

Wilms tumour in a 5 Year Old Child –A Case Report

Balakrishnan P¹, Arun Babu T^{1*}

¹Senior Resident in Pathology, Sri Lakshmi Narayana Institute of Medical Sciences (SLIMS), Puducherry, India.

^{1*}Additional Professor of Pediatrics, All India Institute of Medical Sciences (AIIMS, Mangalagiri, Andhra Pradesh, India.

Abstract

Abdominal lump in a child is a common and worrisome clinical presentation which necessitates many radiological and hematological investigations for diagnosis. Though differential diagnoses are many, detailed history taking and thorough clinical examination can help in diagnosing the organ involved before doing investigations. We are presenting a case of Stage 2 Wilms tumour in a 5 year old child presented with abdominal lump and pallor

Keywords: Malignant renal tumour, Wilms Tumour, children, Abdominal Lump

Address for correspondence: Arun Babu T, Postgraduate, Additional Professor of Pediatrics, All India Institute of Medical Sciences, AIIMS, Mangalagiri, Andhra Pradesh, India.

E-mail: babuarun@yahoo.com

How to cite this article: Balakrishnan P, Arun Babu T, Wilms tumour in a 5 year Old Child. Int J Clinicopathol Correl. 2023;7:1:15-17.

Submitted: 12-Jan-2023 **Revised:** 22-Jan- 2023 **Accepted:** 15-Feb-2023 **Published:**27-Feb-2023

Introduction

Renal mass usually present as abdominal lump in children. The other presenting symptoms can be due to coexisting anemia or metastasis in case of renal malignancy. Early diagnosis and initiation of treatment of childhood malignant renal tumours is necessary to prevent metastasis and tumour rupture. Nephroblastoma or Wilms Tumour (WT) is the most common renal malignancy in childhood and is an embryonic chemosensitive tumour predominantly diagnosed in under 5 children. The incidence of Wilms tumour is 7.8 cases per million children with peak incidence at 2-5 years of age (1).

We are reporting a case of stage 2 wilms tumour with renal vein thrombus in 5 year old female child with help of radiological and pathological investigation .

mother with complaints of painless, nonprogressive abdominal lump for 1 month and pallor. There was no history of fever, trauma, hematuria, any other swelling in body. There was no significant past and family history. On examination, she had severe pallor. Abdominal examination showed a nontender mobile, bimanually palpable mass extending from left hypochondrium upto 4 cm above left iliac crest (Figure-1a). There was no hepatomegaly, ascites, no congenital anomalies in the child.

Hematological investigations showed microcytic hypochromic anemia of severe degree. Urine microscopy showed plenty of RBCs indicating microscopic hematuria.

Case Report

A 5 year old female child was brought by

This is an open access journal, and articles are distributed under the terms of the Creative Commons Attribution-NonCommercial 4.0 International License, which allows others to remix, tweak, and build upon the work non-commercially, as long as appropriate credit is given and the new creations are licensed under the identical terms.

DOI: <https://doi.org/10.56501/intjclinicopatholcorrel.v7i1.837>
Copy right © 2023 Balakrishnan P. Arun Babu T

Biochemical blood investigations were normal. We considered the differential diagnosis of abdominal lump arising from kidney in a child such as Wilms tumour, neuroblastoma, clear cell sarcoma, polycystic kidney disease. We proceeded with Computer tomography of abdomen and chest. CECT abdomen showed a large polylobulated solid lesion of 15x12x15cm arising from left kidney with areas of necrosis and calcification, pushing bowel loops and aorta to right side, encasing left renal vessels and is heterogeneously enhancing, thus suggesting the possibility of Wilms tumour/clear cell sarcoma (Figure-1b). Other kidney was normal and CT chest was normal.

CT guided FNAC of left renal tumour showed features of small round blue cell tumour. After correcting anemia by blood transfusion, left Radical nephrectomy and jejunojejunal anastomosis was done as postoperative period was uneventful.

Grossly, tumour has nodular surface with a segment of bowel attached. Cut surface was lobulated, grey tan (Figure-1c). Histopathological examination showed tumour made of triphasic components such as blastemal, stromal and epithelial elements in the form of immature glomeruli and tubule formation (Figure-1d). Tumour thrombus was seen in renal vein. There was no evidence of anaplasia and nephrogenic rests in tumour. The diagnosis of Stage 2 Wilms tumour with favourable histology was made. Child underwent postoperative adjuvant chemotherapy with actinomycin D and vincristine as per NWTSG treatment protocol. Child is doing well with no evidence of recurrence or metastasis and is under regular follow up with ultrasound examination of contralateral kidney.

Discussion

Wilms tumour is associated with syndromes like WAGR Syndrome, Denys Drash Syndrome and Beckwith weidmann

syndrome (2). Screening of children with congenital anomalies and family history of wilms tumour by regular physical examination by pediatric specialist and ultrasound examination of abdomen at an interval of 3-4 months is necessary till 8 years of age (3). There were no congenital anomalies in our case.

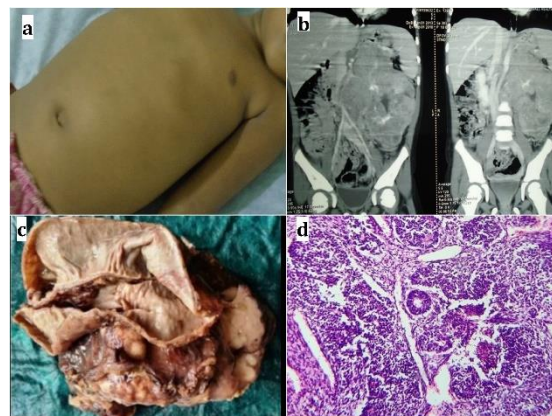


Figure1: a. A case 5 year old female child presented with abdominal lump in extending from left hypochondrium to left iliac crest. b. CT Abdomen and pelvis showing a large polylobulated tumour arising from left kidney with intratumoral calcification. c. Gross photograph of left radical nephrectomy specimen with adhered part of intestine measuring 12cm. Specimen had nodular external surface. d. Microscopic photograph from tumour showing abortive tubular epithelial elements (yellow arrow) and blastemal elements composed small round blue blastemal cells (green arrow)(H&E stain ,40X)

A symptomatic palpable abdominal mass in child incidentally noticed by mother is the most common clinical presentation as seen in the present case (4). CT abdomen is the best investigation to assess the extent and size of tumour, tumour rupture involvement of abdominal vessels and lymphnodes thereby helping in staging of tumour (5). In the present case, we suspected wilms tumour after doing CECT abdomen.

Pathologist has to mention about presence of nephrogenic rests in tumour, anaplastic foci, renal vein tumour thrombus in histopathology report. Presence of nephrogenic rests increases the risk of development of WT in contralateral kidney which necessitates the long term follow up of child with ultrasound examination of contralateral kidney at regular intervals. In our case, there was no nephrogenic rest. (6) WT has 90-95% survival rate when treated at early stages. Early stage of tumour and favourable histological features were good prognostic factors in the present case.

Conclusion

Wilms Tumour is the most common renal malignancy in childhood. Palpable abdominal lump is the most common presentation Diagnosis is by radiological and pathological investigations. Multidisciplinary approach is needed for early diagnosis and effective treatment of pediatric wilms tumour

Acknowledgement: We would like to thank Sri Lakshmi Narayana Institute of Medical Sciences (SLIMS), Puducherry, India. All India Institute of Medical Sciences (AIIMS), Mangalagiri, AndhraPradesh, India. for supporting us in completing this case report

Conflict of interest: Nil

Source of funding: Nil

References

- 1.Rathod G, Shah K. Wilms' tumor in 3 years old female patient - A case report. IAIM, 2017; 4: 244-7.
2. Davidoff AM. Wilms tumor. Adv Pediatr. 2012;59:247-67.
- 3.Scott RH, Walker L, Olsen ØE, Levitt G, Kenney I, Maher E et al. Surveillance for Wilms tumour in at-risk children: pragmatic recommendations for best practice. Arch Dis Child. 2006;91:995-9.
- 4.Tongaonkar HB, Qureshi SS, Kurkure PA, Muckaden MA, Arora B, Yuvaraja TB.

Wilms' tumor: An update. Indian J Urol. 2007;23:458-66.

5.Khanna G, Naranjo A, Hoffer F, Mullen E, Geller J, Grattias EJ et al. Detection of preoperative wilms tumor rupture with CT: a report from the Children's Oncology Group. Radiology. 2013;266:610-7.

6.Hennigar RA, O'Shea PA, Grattan-Smith JD. Clinicopathologic features of nephrogenic rests and nephroblastomatosis. Adv Anat Pathol. 2001;8:276-89.