



Original Research

**Nuclear Changes in Controlled and Uncontrolled Type-2 Diabetic Patients In Buccal Exfoliative Cytology Smears Using Pap And Giemsa Staining – A Comparative Study**

<sup>1</sup>Hasmath Aafreen, <sup>2</sup>Anoop Kumar

*1-General Practitioner, 2-Associate Professor, Kerala University of Health Science, Kerala*

*How to cite: Aafreen H, Kumar A., Nuclear Changes in Controlled and Uncontrolled Type-2 Diabetic Patients In Buccal Exfoliative Cytology Smears Using Pap And Giemsa Staining – A Comparative Study. Int J Histopathol Interpret 2024; 13(1):1-5.*

*DOI: <https://doi.org/10.56501/intjhistopatholinterpret.v13i1.1029>*

*Received:18/02/2024*

*Accepted:24/02/2024*

*Web Published:26/02/2024*

**Abstract**

**Background:** Diabetes is a third leading cause of mortality and morbidity in the world. Oral exfoliative cytology may be a more appropriate adjunctive diagnostic tool in conditions like diabetes mellitus, where the invasive techniques lose viability. Exfoliative cytology helps to detect cellular aging, cell atrophy, alterations in nucleus and cytoplasm, binucleation and occasional karyorrhexis in type-2diabetic patients which proves to be a valuable tool for early diagnosis of diabetes. The purpose of this research was to develop a new method for an early diagnosis of diabetes mellitus by exfoliative cytology using PAP stain and GIEMSA stains which is a nuclear specific stain. The aim of the study was to compare the exfoliative cytology of oral mucosa in controlled and uncontrolled type-2 diabetic patients using PAP stain and GIEMSA stain detect the nuclear and cytoplasmic changes.

**Materials And Methods:** The smears were obtained from buccal mucosa of the mouth in total of 25 individuals out of which 10 are controlled (<120 mg/dl) and 10 are uncontrolled (>130 md/dl) diabetic patients and 5 normal individuals. These smear samples was obtained from the clinical lab of Saveetha Dental College.

**Results:** The nuclear changes include nuclear bud, binucleate/micronucleate, karyolysis, increased nuclear cytoplasmic ratio & hyperchromatism. The binucleated cells were found to have higher differences between controlled & uncontrolled whereas karyorrhexis showed no significant changes between controlled & uncontrolled diabetes.

**Conclusion:** This is a preliminary study conducted to analyse the potential interaction between the nuclear changes and the amount of genetic damage caused in diabetes. However, our result clearly demonstrated that uncontrolled diabetic patients have significantly more genetic damage (in terms of MN frequency) compared to controlled diabetic patients. This indicates than MN may be a useful constituent in a panel of biomarkers for the risk of diabetes.

**Keywords:** Exfoliative cytology, Diabetes, PAP stain and GIEMSA stains.

---

**Address for Correspondence:**

*Dr. Anoop Kumar*

*Associate professor,*

*Kerala University of Health Sciences, Kerala*

*Email: [anok10@gmail.com](mailto:anok10@gmail.com)*

## INTRODUCTION

Diabetes is a third leading cause of mortality and morbidity in the world. Diabetes is one of the most common endocrine metabolic disorders and its prevalence has been increasing worldwide. Oral exfoliative cytology may be a more appropriate adjunctive diagnostic tool in conditions like diabetes mellitus, where the invasive techniques lose viability [1]. Exfoliative cytology helps to detect cellular aging, cell atrophy, alterations in nucleus and cytoplasm, binucleation and occasional karyorrhexis in type-2 diabetic patients which proves to be a valuable tool for early diagnosis of diabetes. Using exfoliative cytology it has been previously studied; morphological changes suffered by oral epithelial cells in diabetics, results which are higher and significant when are compared to healthy patients. Genotoxicity on diabetic patients cause these nuclear changes in an individual. DM2 has been associated with elevated levels of DNA damage, increased susceptibility to mutagens, and a decreased efficacy of DNA repair, causing genomic instability and consequently cancer. However, the mechanism underlying this association is unclear [2]. Our study aimed to compare the exfoliative cytology of oral mucosa in controlled and uncontrolled type-2 diabetic patients to detect the nuclear changes using PAP and GIEMSA as a tool in early diagnosis of diabetes mellitus.

## MATERIALS AND METHODS


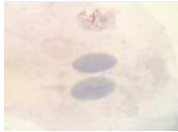
The smears were obtained from buccal mucosa of the mouth in total of 25 individuals out of which 10 are controlled (<120 mg/dl) and 10 are uncontrolled (>130 mg/dl) diabetic patients and 5 normal individuals. These smear samples were obtained from the clinical lab of Saveetha Dental College. Oral samples were obtained by a wooden paddle or a special brush called cytobrush, whose objective is to obtain the largest possible amount of cell samples. The oral smears were stained with PAP and GIEMSA stains. The nuclear changes were evaluated from 300 cells under 40X in light microscopy and image analysis was done to detect the nuclear and cytoplasmic changes. The nuclear changes were evaluated from 300 cells under 40X in light microscopy and image analysis was done to detect the nuclear and cytoplasmic changes.

## RESULTS

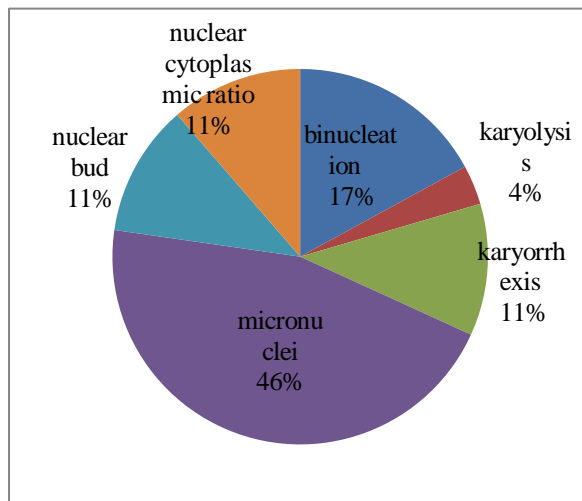
The nuclear changes include nuclear bud, binucleated/micronucleated, karyolysis, increased nuclear cytoplasmic ratio & hyperchromatism. The cells showed various nuclear and cytoplasmic changes in the group 1 and group 2 patients which is tabulated in Table 1 & Table 2 respectively.

NUCLEAR CHANGES	UNCONTROLLED	CONTROLLED
Micronucleated	14	10
Nuclear bud	5	2
Binucleated	9	1
Karyolysis	1	0
Karyorrhexis	3	3
Increased nuclear cytoplasmic ratio	3	1
Hyperchromatism	1	0

**Table 1: Showing nuclear changes seen in Pap staining**

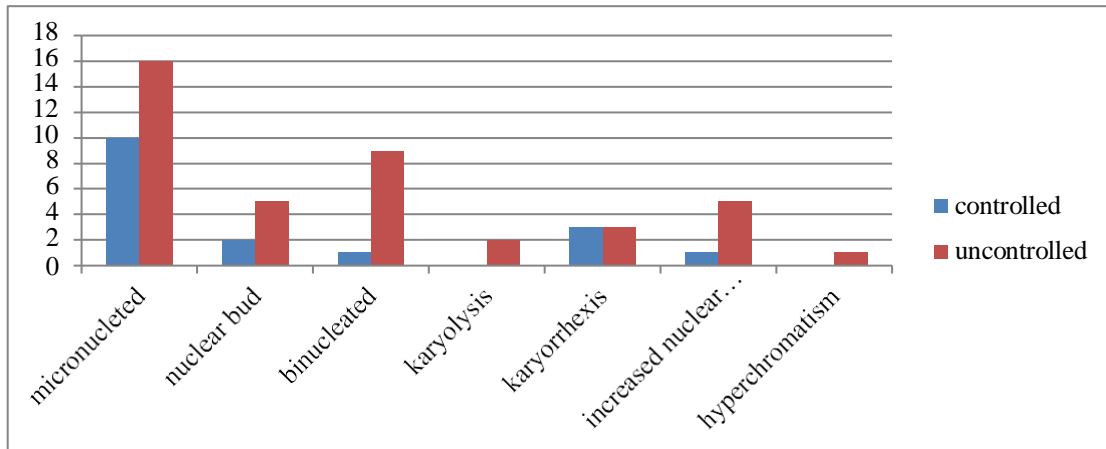
	UNCONTROLLED	CONTROLLED
Micronucleated	3	3
Nuclear bud 	0	0
Binucleated 	0	1
Karyolysis	1	0
Karyorrhexis	3	0
Increased nuclear cytoplasmic ratio	3	0
Hyperchromatism	0	0

**Table 2: Showing nuclear changes seen in Giemsa staining**



**Graph 1: Showing the percentage of nuclear changes in Type-2 diabetes patients**

Among the nuclear changes, Micronulcei was predominantly noted with 46% followed by Binucleation (17%) whereas other features like nuclear bud, increased nuclear cytoplasmic ratio & karyorhexis accounts for 11%. The least feature was karyolysis which accounts for only 4% (Graph 1).



**Graph 2: Showing the frequency of nuclear changes in controlled & uncontrolled Diabetes Mellitus**

The changes in the nuclei showed varied frequencies between controlled & uncontrolled type-2 diabetes patients. The binucleated cells were found to have higher differences between controlled & uncontrolled whereas karyorrhexis showed no significant changes between controlled & uncontrolled diabetes (Graph 2).

## DISCUSSION

In this study, we performed microscopic analyses of the oral epithelium in type II diabetic patients, as a result of a lack of prior works regarding this issue and, primarily, because of the important role that oral exfoliative cytology could play in the diagnosis, prevention, and control of the disease usually is a sign of genotoxic events and chromosomal instability.

Micronuclei are commonly seen in cancerous cells and may indicate genomic damage events that can increase the risk of developmental or degenerative diseases [3,4]. Nuclear anomalies such as nucleoplasmic bridges (NPBs) and nuclear buds (NBUDs) are biomarkers of genotoxic events and chromosomal instability. The increased glycosylation seems to induce oxidative damage in the DNA of the diabetic patients, which manifests as an increased micronuclei frequency. This has a potential to be used as a biomarker for subsequent diabetic complications [5,6] Binucleated cells are cells that contain two nuclei. This type of cell is most commonly found in cancer cells and may arise from a variety of causes. Binucleation can be easily visualized through staining and microscopy [7].

Karyorrhexis (nuclei fragmentation) occurs due to the toxins, infections& also cause karyolysis (cell death). Increased nuclear cytoplasmic ratio seen more significant in uncontrolled patients.

Based on the results of the present study, there is a significant difference in nuclear and cytoplasm size, the ratio of nuclear to cytoplasm ratio in diabetic patients compared to the healthy persons. It seems that diabetes results in creating quantitative cytomorphometric changes in the oral mucosa. In this study, the ratio of nuclear to cytoplasm size was bigger. It is supposed that cell's size in diabetic patients is smaller than that of the healthy persons. On the other hand, epithelial cells of the oral mucosa are atrophied in diabetic persons and the size of nucleus and cytoplasm decrease, such that the formation of multiple wounds and oral infections indicate the atrophy of the oral mucosa in diabetics. The number of micronuclei (MN) has been mainly used as a biomarker in peripheral blood lymphocytes to evaluate genotoxic risks in the work environment [8,9]. MNs are cytoplasmic chromatin masses with the appearance of small nuclei that arise from chromosomal fragments or intact whole chromosomes that lag behind at the anaphase stage of cell division. PAP and GIEMSA stains are used to differentiate the nuclear changes seen in controlled & uncontrolled diabetic patients. Though GIEMSA being a nuclei specific stain, due to high debris the changes were not appreciated as in PAP staining.

## CONCLUSION

This is a preliminary study conducted to analyse the potential interaction between the nuclear changes and the amount of genetic damage caused in diabetes. However, our result clearly demonstrated that uncontrolled diabetic patients have significantly more genetic damage (in terms of MN frequency) compared to controlled diabetic patients. This indicates that MN may be a useful constituent in a panel of biomarkers for the risk of diabetes.

## Financial support and sponsorship:

Nil

## Conflicts of interest :

There are no conflicts of interest

## REFERENCES

1. César Rivera and Camila Núñez-de-Mendoza, Exfoliative cytology of oral epithelial cells from patients with type 2 diabetes: cytomorphometric analysis, international journal of clinical and experimental medicines Int J ClinExp Med, 2013; 6(8): 667-678.
2. Sandra Alberti et al, Exfoliative cytology of the oral mucosa in type II diabetic patients: morphology and cytomorphometry, Journal of Oral pathology & Medicine, Vol 32, Issue 9, Oct 2009; pages 538-543.
3. Shareef BT, Ang KT, Naik VR. Qualitative and quantitative exfoliative cytology of normal oral mucosa in type 2 diabetic patients. Med Oral Patol Oral Cir Bucal 2008;13:E693-6.
4. Patlak M. New Weapons to Combat an Ancient Disease: Treating Diabetes. FASEB J 2002;16:1-12.
5. Kumar V, Cotran RS, Robbins SL. Robbins Basic Pathology. 7 th ed. Philadelphia, PA: Elsevier Inc; 2005. p. 12-647.
6. Orellana-Bustos AI, Espinoza-Santander IL, Franco-Martínez ME, Lobos-James-Freyre N, Ortega-Pinto AV. Evaluation of keratinization and AgNORs count in exfoliative cytology of normal oral mucosa from smokers and non-smokers. Med Oral 2004;9:197-203.
7. Nayar AK, Sundharam BS. Cytomorphometric analysis of exfoliated normal buccal mucosa cells. Indian J Dent Res 2003;14:87-93.
8. Webster M, Witkin KL, Cohen-Fix O. Sizing up the nucleus: Nuclear shape, size and nuclear-envelope assembly. J Cell Sci 2009;122:1477-86.
9. Ycas M, Sugita M, Bensam A. A model of cell size regulation. J TheorBiol 1965;9:444-70.



Published by MM Publishers  
<https://www.mmpubl.com/ijhi>

This is an open access journal, and articles are distributed under the terms of the Creative Commons Attribution-Non Commercial 4.0 International License, which allows others to remix, tweak, and build upon the work non-commercially, as long as appropriate credit is given and the new creations are licensed under the identical terms.  
To view a copy of this license, visit <http://creativecommons.org/licenses/by-nc/4.0/> or send a letter to Creative Commons, PO Box 1866, Mountain View, CA 94042, USA.

Copyright ©2024 Aafreen H, Kumar A