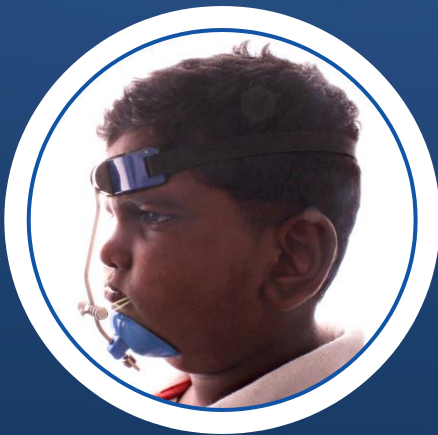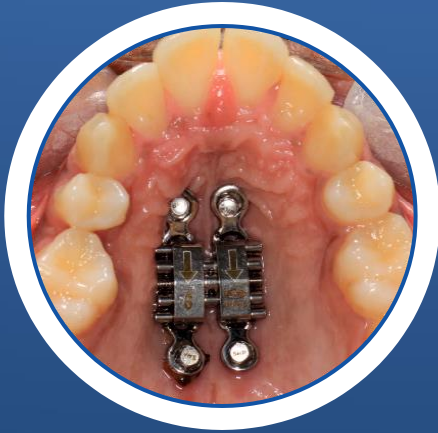

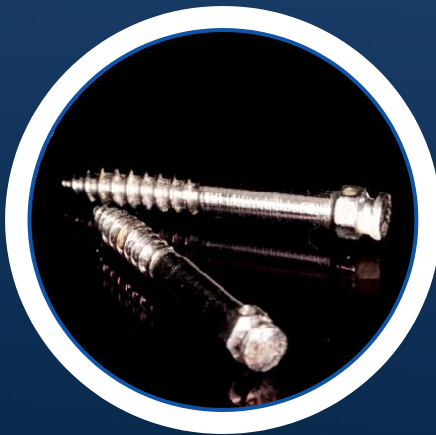
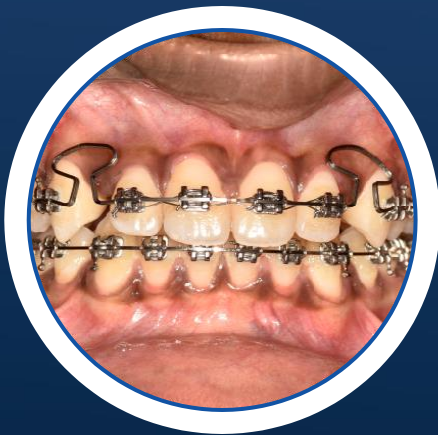Volume 13 Issue-1
January - March 2022

ISSN : 2349 - 5243
E-ISSN : 2542 - 5579



International Journal of
**Orthodontic
Rehabilitation**



COMPARATIVE EVALUATION OF WOUND HEALING FOLLOWING GINGIVECTOMY USING DIODE LASER AND ERBIUM, CHROMIUM-DOPED YTTRIUM, SCANDIUM, GALLIUM AND GARNET (Er: Cr: YSGG) LASER IN PATIENTS UNDERGOING FIXED ORTHODONTIC TREATMENT- A RANDOMIZED CONTROLLED TRIAL.

Inchara Naidu¹, Priya Lochana Gajendran²,

Saveetha Dental College and Hospitals,

Saveetha Institute of Medical and Technical Sciences,

Saveetha University, Chennai 600 077

ABSTRACT:

Aim: The aim of the current study is to compare the healing following gingivectomy procedures using the Diode system and Er:Cr:YSGG lasers in patients undergoing fixed orthodontic treatment.

Methodology: The study is a single center randomized controlled clinical study with a sample size of 40 patients who underwent gingivectomy using lasers. The patients were divided into two groups randomly (Group A= 20 and Group B= 20). Group A patients had undergone gingivectomy using diode laser (BIOLASE EPIC X, 940 nm) and Group B patients had undergone gingivectomy using Er:Cr:YSGG laser (Waterlase, 2780nm). The patients were followed at day 3, day 7 and day 14. The wound healing was assessed post laser application using a healing index by Landry et al at different time intervals. Data were entered in Microsoft Excel spreadsheet and analyzed using SPSS software (IBM SPSS Statistics, Version 20.0, Armonk, NY: IBM Corp.). Independent t test was used to compare the mean healing index score between the groups. Repeated measures ANOVA and Post hoc Bonferroni test was used for comparison of mean healing index scores of Group A and B at different time periods

Result: When comparing the healing index at day 3 between the groups, there was no significant difference between the diode laser and erbium laser group (P = 0.24). Similarly at day 7 and at day 14, there were no significant differences between the groups (P= 0.20), (P= 0.18) at day 7 and day 14 respectively. When comparing the healing index score of gingivectomy with diode laser between different time intervals, there was a statistically significant healing seen at day 14 (P = 0.001). The healing at day 14 was significantly better than day 3 and day 7 in the erbium laser group (P = 0.001).

Conclusion: Within study limits it is concluded that Er:Cr:YSGG lasers have better healing compared to diode lasers following laser assisted gingivectomy although the results are not statistically significant. Thus, the use of laser is an effective treatment approach in the management of orthodontic associated gingival enlargement.

Keywords: Diode, Er:Cr:YSGG; Gingivectomy; Healing; Innovative technology; Laser.

How to Cite This Article: Inchara N, Priya LG, Comparison of Healing Following Gingivectomy Procedures Using Diode Laser and Erbium, Chromium-Doped Yttrium, Scandium, Gallium and Garnet (Er:Cr:Ysgg) Laser – In Patients Undergoing Fixed Orthodontic Treatment- A Randomized Control Clinical Trial. *Int J Orthod Rehabil* 2022; 13:1:16-22.

INTRODUCTION:

Gingival enlargement is one of the most common problems associated with fixed orthodontic treatment. Predisposing factors such as mechanical irritation due to molar bands, luting cements, food impaction and poor oral hygiene maintenance may result in orthodontic induced gingival enlargement as suggested by Kloehn and Pfeifer.^[1] Chronic inflammatory gingival enlargement may affect the occlusion, phonetics, esthetics and may delay the orthodontic tooth movement process.^[2] It can be localized affecting only the interdental papilla or slowly can become generalized affecting all the teeth, varying from mild enlargement of isolated interdental papillae to segmental or uniform and marked enlargement affecting one or both jaws. This enlargement in turn affects the ability of the patient to maintain good oral health, which needs periodontal evaluation and intervention.^[3]

The initial line of treatment would be to perform non-surgical phase I periodontal therapy, which may not provide successful results when the enlargement is extensive and patient's compliance is less.^[4] Surgical approaches such as gingivectomy is commonly preferred for such cases. Gingivectomy can be performed using conventional scalpel or with lasers. The elimination of the pseudo pockets is considered as the therapeutic endpoint of all these procedures.^[5] The conventional external bevel gingivectomy is although routinely performed it does not provide adequate hemostasis, especially when working with highly inflamed tissues.^[6]

In the recent times, lasers have been a cutting-edge technology in dentistry. The indications of laser assisted procedures have been expanded to all branches of dentistry as hemostasis, less postoperative edema, bactericidal effect at the surgical site, less suturing, faster healing and less postoperative discomfort are the most common advantages of using dental lasers. Diode lasers are the commonly used soft tissue surgical procedures.^[7] The erbium family of lasers is used for oral hard tissue and soft tissue surgical procedures. They can safely ablate both soft and hard tissues with water irrigation and are suitable for periodontal therapies like scaling, debridement, and bone surgery, with minimum heat effect.^[8-10]

The use of lasers for gingivectomy procedures has shown predictable results. However, literature search revealed that there no studies comparing the diode laser-assisted gingivectomy versus Er:Cr:YSGG assisted gingivectomy in orthodontic patients, and the majority of studies investigating laser-assisted surgery have some limitations as they are not randomized, they are not prospective.^[11-13] The null hypothesis underlying this investigation is that there is no difference in wound healing comparing 940nm diode laser and 2780nm Er:Cr:YSGG laser for gingivectomy procedures. Our team has extensive knowledge and research experience that has translated into high quality publications.^[14-33] The aim of the current study is to compare the healing following gingivectomy procedures using the Diode laser and Er:Cr:YSGG lasers in patients undergoing fixed orthodontic treatment.

MATERIALS AND METHODS:

STUDY DESIGN AND SETTING:

This single centric randomized controlled clinical trial was carried out on patients who underwent surgical dental implant placement procedures in Department of Periodontology, Saveetha Dental College and Hospitals, Chennai. The study was carried out during the period of July 2020 to January 2021. The study was approved by the Institutional review board and ethical committee. Patients were explained about the nature of the study and an informed consent was obtained following their willingness to participate in the study. The study was performed following the Consolidated Standards of Reporting Trials (CONSORT). Sample size was calculated according to the study done by Mavrogiannis et al. (type I error rate of 5% and a power of 80%).^[12]

INCLUSION AND EXCLUSION CRITERIA:

A total of 40 patients, who had been referred to the department of Periodontics for the management of orthodontics associated gingival enlargement were included in this study. Gingival overgrowth diagnosis was defined as presence of quadratic anterior teeth (crown width/length ratio ≤ 0.85), gingival margin located incisal to the tooth cervical convexity, and presence of probing pocket depth (PPD) ≥ 4 mm coronal to the cement-enamel junction (CEJ).^[34,35] To exclude cases with altered passive eruption, in which bone crest was at the same level of the CEJ—a trans-gingival probing was performed after anesthesia. Patients taking calcium channel blockers, anticonvulsants, or immune-suppressants; patients currently pregnant or lactating; and patients with any medical condition affecting wound healing were excluded from the study.

RANDOMIZATION AND STUDY PROTOCOL:

The patients requiring gingivectomy were randomly allocated into two groups. Randomization was done using Random chit method. Group A had 20 patients who had undergone gingivectomy using Diode laser and group B had 20 patients who had undergone gingivectomy using Er:Cr:YSGG lasers. Following the gingivectomy procedure, the wound healing was assessed post laser application using a healing index by Landry et al., [Table 1] which grades the wound on a scale of 1–5, where 1 indicates very poor healing and 5 indicates excellent healing.^[36] All gingivectomy procedures were performed by one examiner whereas healing index scores were given by a different examiner who was blinded about the study group participants. The healing index score were recorded at day 3, day 7 and at day 14.

Table 1 – Wound healing index scores

Healing index score	Clinical findings
Very Poor	Tissue color: ≥50% of gingiva red Response to palpation: Bleeding Granulation tissue: Present Incision margin: Not epithelialized, with loss of epithelium beyond incision margin.
Poor	Tissue color: ≥50% of gingiva red Response to palpation: Bleeding Granulation tissue: Present Incision margin: Not epithelialized, with connective tissue exposed
Good	Tissue color: ≥25% and <50% of gingiva red Response to palpation: No bleeding Granulation tissue: None Incision margin: No connective tissue exposed
Very good	Tissue color: <25% of gingiva red Response to palpation: No bleeding Granulation tissue: None Incision margin: No connective tissue exposed
Excellent	Tissue color: All tissues pink Response to palpation: No bleeding Granulation tissue: None Incision margin: No connective tissue exposed

LASER GINGIVECTOMY PROTOCOL FOR THE TWO TYPES OF LASERS:

DIODE LASER PROTOCOL:

After the area was adequately anaesthetized with 2% lignocaine and 1:80 000 adrenaline, the clinician and the patient put on safety precautions such as safety glasses for the concerned wavelength and a laser-assisted gingivectomy was performed (940 nm diode laser; Biolase Epic X). The laser unit, comprising of a 400 µm disposable tip, was used in a contact mode with a setting of 1–1.5 W average power in gated pulsed mode along the previously demarcated area with a paint brush-like strokes progressing slowly to remove the gingival tissue and expose adequate amount of tooth structure. During the entire procedure, the tip was constantly checked for any debris of the ablated tissues and was cleaned with sterile moist gauze. High-volume suction was used to evacuate the laser plume.

ERBIUM LASER PROTOCOL:

The procedure was done only under topical anesthetic gel(Lignocaine 2%).In this group the gingivectomy procedure was performed using the Er:Cr:YSGG laser with the following fixed operation parameters: 300 my, 18 Hz, water cooling at 40%, energy density per pulse: 38.21 J/cm², tip size: MZ5 tip in contact mode.

Following the gingivectomy procedures, post-operative instructions were given and they were prescribed analgesics (Aerosol- P, thrice daily for three days). They were instructed to take the medicine only if required.

STATISTICAL ANALYSIS:

Data were entered in Microsoft Excel spreadsheet and analyzed using SPSS software (IBM SPSS Statistics, Version 20.0, and Armonk, NY: IBM Corp.). Descriptive statistics were used for data summarization and presentation. Shapiro Wilk test were used to determine the normality of the data. Independent t test was used for mean age wise and mean healing index score between the groups. Chi-square test was used for gender wise comparison between groups. Repeated measures ANOVA and Post hoc Bonferroni test was used for comparison of mean healing index scores of Group A and B at different time periods. The level of statistical significance was set at a value of P < 0.05.

RESULTS:

The current study comprised 40(23 males and 17 females) patients with a mean age 20.70±2 years for group A and 20.75 ±1.74 in group B. All the subjects reported for the follow up appointments. Healing took place uneventfully with no patients reporting any adverse postoperative complications. The mean healing index scores for both the groups at day 3, 7 and day 14 is represented as means in Table 2.

When comparing the healing index at day 3 between the groups, there was no significant difference between the diode laser and erbium laser group (P = 0.24). Similarly at day 7 and at day 14, there were no significant differences between the group with P values 0.20 and 0.18 at day 7 and day 14 respectively. [Table 2] When comparing the healing index score of Gingivectomy with Diode laser between different time intervals, there was a statistically significant healing was seen at day 14. [Table 3] The healing at day 14 was significantly better than day 3 and day 7 in the erbium laser group. [Table 4]

TABLE 2 - Comparison of Healing between Diode system and Er: Cr: YSGG using paired t – test at day 3, day 7 and at day 14.

Time intervals	Groups	Mean	Std. Deviation	Independent t test value	P value
3rd day	Gingivectomy with Diode laser	2.80	0.410	-1.17	0.24
	Gingivectomy with Erbium laser	2.95	0.39		
7th day	Gingivectomy with Diode laser	3.55	0.60	-2.43	0.20
	Gingivectomy with Erbium laser	4.00	0.56		
14th day	Gingivectomy with Diode laser	4.60	0.50	-1.37	0.18
	Gingivectomy with Erbium laser	4.80	0.41		

*P value less than 0.05 - statistically significant

Table 3: Comparison of Healing index score of Gingivectomy with Diode laser between different time intervals

	Time intervals	Mean	Std. Deviation	Repeated Measures ANOVA			
				Wilks Lambda	F value	Effect size	P value
Gingivectomy with Diode laser	3rd day	2.80	0.410	0.09	82.18	0.90	0.001
	7th day	3.55	0.60				
	14th day	4.60	0.50				

*P value less than 0.05- statistically significant.

Table 4: Comparison of Healing index score of Gingivectomy with Diode laser between different time intervals.

	Time intervals	Mean	Std. Deviation	Repeated Measures ANOVA			
				Wilks Lambda	F value	Effect size	P value
Gingivectomy with Erbium laser	3rd day	2.95	0.39	0.07	117.73	0.92	0.001*
	7th day	4.00	0.56				
	14th day	4.80	0.41				

*P value less than 0.05 - statistically significant.

DISCUSSION: -

Lasers have become a part of modern dentistry since the past three decades. A wide-ranging assortment of lasers is being used for both soft and hard tissue surgical procedures. The frequently used soft tissue lasers include the carbon dioxide laser (10,600 nm), erbium lasers [erbium-doped yttrium-aluminium-garnet (Er:YAG) laser (2,940 nm) and erbium chromium-doped yttrium-scandium-gallium-garnet (Er:Cr:YSGG) laser (2,780 nm)], neodymium-doped yttrium-aluminium-garnet (Nd:YAG) laser (1,064 nm), the diode group of lasers (800–980 nm) and, the potassium, titanium and phosphate (KTiOPO4, KTP) laser (532 nm).^[37]

The soft tissue lasers can be broadly divided into two types: the deeply penetrating-type lasers (visible and near-infrared spectrum, 532–1,100 nm) that are essentially transmitted through water, showing a lower absorption coefficient in water such as the diode lasers.^[38] The second type are the superficially absorbed lasers (CO2, Er:YAG and Er:Cr:YSGG lasers), in which the laser beam is absorbed in the superficial layer and does not penetrate or scatter deeply. These lasers have the highest absorption coefficient in water and hydroxyapatite, and due to the high-water content of oral mucosa (>90%), they are very effective soft tissue lasers.^[39]

The present study aimed to assess the short-term wound healing between the diode laser and erbium laser. Laser treatment is based on the conversion of light energy into heat through the process of photo thermolysis. The study findings suggest that the wound healing index values are marginally higher in the erbium laser group when compared to the diode laser group at all the time intervals, although the results are not statistically significant. Sanz-Moliner et al. discovered that using an 810-nm diode laser during periodontal care improved wound healing and reduced edema and postoperative discomfort.^[40] Lione et al concluded that the adjunct use of both scalpel gingivectomy and laser gingivectomy was more effective in controlling gingival inflammation than non-surgical periodontal treatment alone at 1, 3 and 6 months in patients with fixed orthodontics associated gingival enlargement.^[41]

Clinical trials have revealed that Er:Cr:YSGG application eliminates the use of surgical sutures, a finding that indicates that laser surgery reduces the surgical period, is associated with minimal bleeding, and decreases the need for analgesic drugs. Pick and Colvard recommended laser gingivectomy due to minimal postoperative discomfort.^[42] Erbium Chromium YSGG (Waterlase) lasers, when used properly, allow us to do surgeries with minimal bleeding, while reducing inherent inflammatory responses during our surgical procedure. The result of our study is also in favor of erbium lasers than the diode lasers.

The diode laser group patients did require minimal infiltration of local anesthesia for the procedure to avoid pain due to lack of thermal relaxation even with minimal operating power parameters. However, the erbium laser group, were given only topical anesthesia for the gingivectomy procedure. The added advantage of coolant used in erbium lasers, results in the most rapid, favorable, and uneventful wound healing due to their precise ablation with minimal thermal effects as well as low inflammatory response.^[42] However, hemostasis is less effective with the erbium lasers because of the minimal tissue denaturation, which guarantees subsequent sufficient bleeding and blood clot formation in the ablated defects and thereby induces favorable wound healing. Overall, erbium lasers provide the highest absorption into water, minimizing the thermal effects on the surrounding tissues during irradiation, but the cost, laser portability and movement and less clear-cut incision morphology diode lasers are the potential drawbacks in clinical practice.

The novelty of this study is to assess the wound healing in gingivectomy patients using two different laser systems. Wound healing index given by Landry et al have been used previously to assess healing following gingival recession management and in the field of oral surgery. The present study has certain limitations. The healing following laser gingivectomy was assessed only for the two weeks, however the gingival enlargement and recurrence should be followed for periods of 6 months to 1 year prospectively. This could be the future directions of the present study.

CONCLUSION:

Within study limits, it is concluded that when compared to diode laser, the Er: Cr: YSGG laser had better wound healing although the results were not statistically significant. Thus, the use of laser is an effective treatment approach in the management of orthodontic associate gingival enlargement.

ACKNOWLEDGEMENT:

We would like to thank all the participants who took part in the study. We also thank Saveetha dental college and hospitals for their constant help and support.

CONFLICT OF INTERESTS:

All the authors declare that there was no conflict of interest in the present study.

SOURCE OF FUNDING:

The present project is funded by Saveetha Dental College and Hospitals, Saveetha Institute of Medical and Technical Sciences.

REFERENCES:

1. Kloehn JS, Pfeifer JS. The effect of orthodontic treatment on the periodontium. *Angle Orthod.* 1974;44:127-34.
2. Romero M, Albi M, Bravo LA. Surgical solutions to periodontal complications of orthodontic therapy. *J Clin Pediatr Dent.* 2000;24:159–163.
3. De Oliveira Guare´ R, Costa SC, Baeder F, De Souza Merli LA, Dos Santos MT. Drug-induced gingival enlargement: Biofilm control and surgical therapy with gallium–aluminum– arsenide (GaAlAs) diode laser—A 2-year follow-up. *Spec Care Dentist.* 2010;30:46–52.
4. Kravitz ND, Kusnoto B. Soft-tissue lasers in orthodontics: an overview. *Am J Orthod Dentofacial Orthop.* 2008; 133:S110–S114.
5. Öncü E. Comparison of gingivectomy procedures for patient satisfaction: Conventional and diode laser surgery. *Selcuk Dent J.* 2017;4:6–9.
6. Robert A Convissar. *Principles and Practice of Laser Dentistry.* Mosby Elsevier 2011:pp 67-70.
7. Chawla K, Gupta M, Khanna N, Lamba A. Treatment of peri-implantitis around orthodontic miniscrew using Er,Cr: YSGG Laser. *J Dent Lasers.* 2012;6:66-7
8. Magaz VR, Alemany AS, Alfaro FH, Molina JN. Efficacy of Adjunctive Er, Cr:YSGG Laser Application Following Scaling and Root Planing in Periodontally Diseased Patients. *Int J Periodontics Restorative Dent.* 2016; 36:715-721.

9. Stübinger S, Klämpfl F, Schmidt M, Zeilhofer H-F. Lasers in Oral and Maxillofacial Surgery. Springer Nature 2020;p 269.
10. Fekrazad R, Moharrami M, Chiniforush N. The Esthetic Crown Lengthening by Er:Cr:YSGG laser: A Case Series. J Lasers Med Sci. 2018; 9:283-287.
11. Tony N F To, ABakr M Rabie, Ricky W K Wong, Colman P McGrath. The adjunct effectiveness of diode laser gingivectomy in maintaining periodontal health during orthodontic treatment. Angle Orthod. 2013; 83:3-47.
12. Mavrogiannis, M., Ellis, J.S., Seymour, R.A. and Thomason, J.M. The efficacy of three different surgical techniques in the management of drug-induced gingival overgrowth. J. Clin. Periodontol. 2003; 33:677-682.
13. I N Ize-Iyamu, B D Saheeb, B E Edetanlan. Comparing the 810 nm diode laser with conventional surgery in orthodontic soft tissue procedures. Ghana Medical Journal. 2013; 47:107-111.
14. Ramesh A, Varghese S, Jayakumar ND, Malaiappan S. Comparative estimation of sulfiredoxin levels between chronic periodontitis and healthy patients - A case-control study. J Periodontol. 2018; 89:1241-8.
15. Paramasivam A, Priyadharsini JV, Raghunandhakumar S, Elumalai P. A novel COVID-19 and its effects on cardiovascular disease. Hypertens Res. 2020; 43:729-30.
16. S G, T G, K V, Faleh A A, Sukumaran A, P N S. Development of 3D scaffolds using nanochitosan/silk-fibroin/hyaluronic acid biomaterials for tissue engineering applications. Int J BiolMacromol. 2018;120:876-85.
17. Del Fabbro M, Karanxha L, Panda S, Bucchi C, NadathurDoraiswamy J, Sankari M, et al. Autologous platelet concentrates for treating periodontal infrabony defects. Cochrane Database Syst Rev. 2018;11:CD011423.
18. Paramasivam A, VijayashreePriyadharsini J. MitomiRs: new emerging microRNAs in mitochondrial dysfunction and cardiovascular disease. Hypertens Res. 2020; 43:851-3.
19. Jayaseelan VP, Arumugam P. Dissecting the theranostic potential of exosomes in autoimmune disorders. Cell MolImmunol. 2019; 16:935-6.
20. Vellappally S, Al Kheraif AA, Divakar DD, Basavarajappa S, Anil S, Fouad H. Tooth implant prosthesis using ultra low power and low cost crystalline carbon bio-tooth sensor with hybridized data acquisition algorithm. ComputCommun. 2019;148:176-84.
21. Vellappally S, Al Kheraif AA, Anil S, Assery MK, Kumar KA, Divakar DD. Analyzing Relationship between Patient and Doctor in Public Dental Health using Particle Memetic Multivariable Logistic Regression Analysis Approach (MLRA2). J Med Syst. 2018; 42:183.
22. Varghese SS, Ramesh A, Veeraiyan DN. Blended Module-Based Teaching in Biostatistics and Research Methodology: A Retrospective Study with Postgraduate Dental Students. J Dent Educ. 2019; 83:445-50.
23. Venkatesan J, Singh SK, Anil S, Kim S-K, Shim MS. Preparation, Characterization and Biological Applications of Biosynthesized Silver Nanoparticles with Chitosan-Fucoidan Coating. Molecules. 2018;22:1429
24. Alsubait SA, Al Ajlan R, Mitwalli H, Aburaisi N, Mahmood A, Muthurangan M, et al. Cytotoxicity of Different Concentrations of Three Root Canal Sealers on Human Mesenchymal Stem Cells. Biomolecules. 2018; 8:68.
25. Venkatesan J, Rekha PD, Anil S, Bhatnagar I, Sudha PN, Dechsakulwatana C, et al. Hydroxyapatite from Cuttlefish Bone: Isolation, Characterizations, and Applications. Biotechnol Bioprocess Eng. 2018; 23:383-93.
26. Vellappally S, Al Kheraif AA, Anil S, Wahba AA. IoT medical tooth mounted sensor for monitoring teeth and food level using bacterial optimization along with adaptive deep learning neural network. Measurement. 2019;135:672-7.
27. PradeepKumar AR, Shemesh H, Nivedhitha MS, Hashir MMJ, Arockiam S, Uma Maheswari TN, et al. Diagnosis of Vertical Root Fractures by Cone-beam Computed Tomography in Root-filled Teeth with Confirmation by Direct Visualization: A Systematic Review and Meta-Analysis. J Endod. 2021;47:1198-214.
28. R H, Ramani P, Tilakaratne WM, Sukumaran G, Ramasubramanian A, Krishnan RP. Critical appraisal of different triggering pathways for the pathobiology of pemphigus vulgaris-A review. Oral Dis. 2021 Jun 21.
29. Ezhilarasan D, Lakshmi T, Subha M, Deepak Nallasamy V, Raghunandhakumar S. The ambiguous role of sirtuins in head and neck squamous cell carcinoma. Oral Dis. 2022; 28:559-567.
30. Sarode SC, Gondivkar S, Sarode GS, Gadbail A, Yuwanati M. Hybrid oral potentially malignant disorder: A neglected fact in oral submucous fibrosis. Oral Oncol 2021;121:105390
31. Kavarthapu A, Gurumoorthy K. Linking chronic periodontitis and oral cancer: A review. Oral Oncol. 2021;121:105375.
32. Vellappally S, Abdullah Al-Kheraif A, Anil S,

- Basavarajappa S, Hassanein AS. Maintaining patient oral health by using a xeno-genetic spiking neural network. *J Ambient Intell Humaniz Comput.* 2018 ;1-9.
33. Aldhuwayhi S, Mallineni SK, Sakhamuri S, Thakare AA, Mallineni S, Sajja R, et al. Covid-19 Knowledge and Perceptions Among Dental Specialists: A Cross-Sectional Online Questionnaire Survey. *Risk ManagHealthc Policy.* 2021; 7:2851–61.
34. Strrett, J.D., Oliver, T., Robinson, F., Fortson, W., Knaak, B. and Russell, C.M. Width/length ratios of normal clinical crowns of the maxillary anterior dentition in man. *J Clin Periodontol.* 1994;26:153-157.
35. Silva, C.O., Soumaille, J.M., arson, F.C., Progiante, P.S. and Tatakis, D.N. Aesthetic crown lengthening: periodontal and patient centered outcomes. *J Clin Periodontol.* 2015; 42:1126-1134.
36. Landry RG, Turnbull RS, Howley T. Effectiveness of benzydamineHCl in the treatment of periodontal post-surgical patients. *Res Clin Forums* 1988;10:105-18
37. Chmura LG, Convissar RA. Lasers in orthodontics. In: Convissar RA, editor. *Principles and practice of laser dentistry.* 2nd ed. St. Louis: Elsevier; 2016. pp. 203–19.
38. Mizutani K, Aoki A, Coluzzi D, Yukna R, Wang CY, Pavlic V, Izumi Y. Lasers in minimally invasive periodontal and peri-implant therapy. *Periodontol* 2000. 2016;71:185–212
39. Merigo E, Clini F, Fornaini C, Oppici A, Paties C, Zangrandi A. *et al.*, Laser-assisted surgery with different wavelengths: a preliminary ex vivo study on thermal increase and histological evaluation. *Lasers Med Sci.* 2013;28:497–504
40. Sanz-Moliner JD, Nart J, Cohen RE, Ciancio SG. The effect of an 810-nm diode laser on postoperative pain and tissue response after modified Widman flap surgery: A pilot study in humans. *J Periodontol.* 2013; 84:152–8.
41. Lione R, Pavoni C, Noviello A, Clementini M, Danesi C, Cozza P. Conventional versus laser gingivectomy in the management of gingival enlargement during orthodontic treatment: a randomized controlled trial. *Eur J Orthod.* 2020; 42:78-85.
42. Pick RM, Colvard MD. Current status of lasers in soft tissue dental surgery. *J Periodontol* 1993; 64:589-602.