



*Case Report*

***Bimaxillary Molar Distalization Using Clear Aligners To Correct Severe Crowding Without Temporary Anchorage Devices: A Case Report***

*Kun Li<sup>1</sup>, Peng Sun<sup>2</sup>, Hui Li<sup>2</sup>, Deming Yu<sup>1</sup>*

*<sup>1</sup>Fushan Division, <sup>2</sup>Department of Orthodontics, The Affiliated Yantai Stomatological Hospital, Binzhou Medical University, Yantai, China.*

---

**How to cite this article:** Kun Li, Peng Sun, Hui Li, Deming Yu. Bimaxillary Molar Distalization using Clear Aligners to correct severe crowding without Temporary Anchorage Devices: A Case Report. *Int J Orthod Rehabil* 2024; 15 (3) 46-61.

*Doi: 10.56501/intjorthodrehabil.v15i3.1134*

*Received: 17-05-2024.*

*Accepted: 17-08-2024*

*Web Published: 07-10-2024*

---

**ABSTRACT**

The use of clear aligners for molar distalization has been a hot topic in recent years. However, cases of bimaxillary molar distalization without temporary anchorage devices (TADs) are rarely reported. Dental crowding, one of the most common malocclusions in the Asian population, was often corrected by tooth extraction strategies in the past. Currently, in the application of molar distalization with clear aligners by orthodontic professionals, it becomes feasible to circumvent the necessity for tooth extraction or TADs in numerous cases that initially present as markedly crowded. A 29-year-old female sought treatment for dental crowding. Subsequent examination revealed that her upper dentition was moderately crowded, while the lower dentition exhibited severe crowding. The patient declined the extraction treatment option and requested clear aligners based on consideration of esthetics during orthodontic treatment. Drawing from the patient's chief complaint and specific requirements, an orthodontic procedure of bimaxillary molar distalization was implemented. Following the completion of clear aligner treatment, the patient achieved well-aligned teeth and a captivating smile, radiating enhanced esthetics. The satisfactory treatment outcomes confirmed the efficacy of clear aligners for molar distalization. With a well-considered anchorage plan, clear aligners can successfully achieve bimaxillary molar distalization without the necessity of TADs.

**Keywords:** Molar distalization; clear aligners; anchorage design; dental crowding; orthodontic treatment.

---

***Address for Correspondence:***

*Dr. Deming Yu,*

*Associate Professor, Fushan Division,*

*The Affiliated Yantai Stomatological Hospital,*

*Binzhou Medical University, Yantai, China.*

*Email: 15064500100@163.com*

© 2024 Published by MM Publishers

## **INTRODUCTION**

Dental crowding stands as a primary motivating factor driving patients to pursue orthodontic treatment.<sup>[1]</sup> When dealing with a patient presenting malocclusion characterized by moderate to severe crowding, the conventional approach involves contemplating the extraction of premolars to obtain adequate space for tooth alignment.<sup>[2]</sup> Proffit et al indicated that for patients with dental crowding exceeding 10 mm, tooth extraction is nearly deemed necessary for orthodontic treatment. However, when molar distalization can be achieved ideally, the rate of extraction treatment in orthodontic clinical practice might be significantly reduced. Molar distalization can be accomplished using either intraoral or extraoral anchorage methods.<sup>[3-5]</sup> However, extraoral forces always come with significant drawbacks, primarily the requirement for good patient compliance and the detrimental effects on esthetics. To address the constraints, numerous intraoral appliances have been employed for molar distalization. Nevertheless, loss of anchorage is frequently the undesirable by-effect associated with these intraoral techniques, resulting in labial tipping of anterior teeth. To circumvent the potential risk of anchorage loss, the utilization of TADs might be indispensable in the process of molar distalization with conventional fixed appliances.

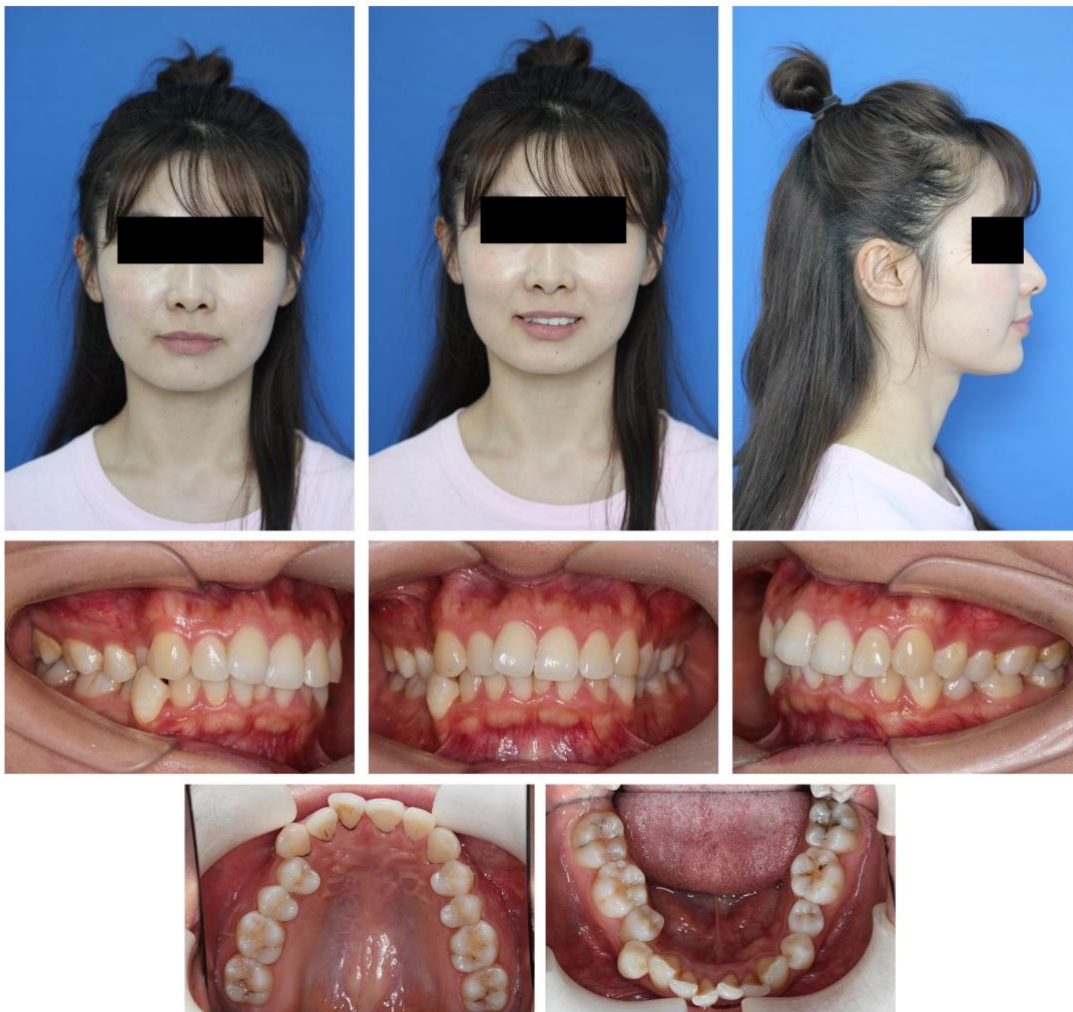In light of the expeditious advancements in clear aligner treatment technology, the indisputable benefits of employing clear aligners for molar distalization have garnered extensive recognition within the field of orthodontics. Initially introduced in orthodontics, clear aligners were designed for the correction of mild crowding. Indeed, at present, their scope of application has expanded to encompass moderate to severe crowding, spanning both extraction and non-extraction cases.<sup>[6]</sup> Simon et al<sup>[7]</sup> documented a notable degree of precision in maxillary molar distalization when employing clear aligners, achieving an accuracy rate of up to 87%. Additionally, studies conducted by Ravera et al<sup>[8]</sup> and Caruso et al<sup>[9]</sup>, which involved the analysis of lateral cephalograms, demonstrated that clear aligners can achieve bodily distalization of maxillary molars by 2-3 mm without noticeable intrusion or tipping. The high efficacy of clear aligners in molar distalization,<sup>[10, 11]</sup> is primarily owing to their comprehensive tooth crown coverage and proclivity to induce bodily movement throughout the process of molar distalization.<sup>[12]</sup> Certainly, within the context where TADS are not employed, the potential for anterior anchorage loss must also be acknowledged when utilizing clear aligners for molar distalization. This concern becomes particularly paramount in clinical cases involving bimaxillary molar distalization, necessitating the implementation of highly effective anchorage control strategies to counteract unforeseen tooth movement.<sup>[13]</sup> To date, numerous case reports have documented the application of clear aligners for mono-maxillary molar distalization without TADs. However, there has been a scarcity of clinical cases reported pertaining to bimaxillary molar distalization.

This case report delineates a non-extraction orthodontic treatment in an adult female patient presenting with moderate to severe dental crowding, wherein clear aligners were deployed to effect bimaxillary molar distalization devoid of TADs. Given the necessity for proper labial movement of the mandibular anterior segment, the mandibular molar distalization was designed to be achieved in the form of reciprocal anchorage. On the other hand, to mitigate the risk of labial tipping of the maxillary incisors during the process of maxillary molar distalization, Class II elastics were incorporated. The treatment outcomes demonstrate that, with a well-planned anchorage strategy, clear aligner treatment can successfully achieve bimaxillary molar distalization without the necessity of utilizing TADs.

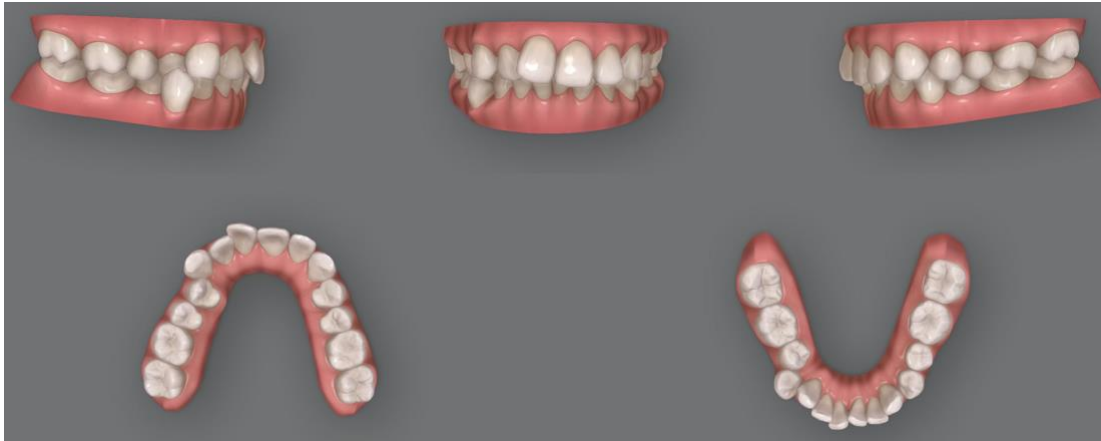
## CASE PRESENTATION

A 29-year-old female presented with the chief complaint of dental crowding. She expressed strong esthetic concerns regarding orthodontic treatment and specifically requested the use of clear aligners. The patient was physically healthy.

Under extraoral examination (Figure 1), the patient presented a nearly balanced facial profile, and the facial proportions fell within the normal range. A subtle deviation of the chin to the right was observed, and the right side of the face appeared slightly more prominent than the left. During a smile, the midlines of the upper and lower dentition showed an approximate 2mm deviation to the right when compared to the facial midline. There were no notable symptoms indicating temporomandibular joint disease. Under intraoral examination (Figures 1 and 2), she exhibited bilateral Class I molar and Class II canine relationships, accompanied by an overbite of 4.3 mm and an overjet of 3.6 mm. The upper dentition displayed a moderate level of crowding, while the lower dentition exhibited severe crowding, and both the upper and lower arches showed narrow configurations. A pronounced deep curve of Spee could also be observed. The oral hygiene status was suboptimal, and there were noticeable deposits of pigments and dental calculus present. Multifocal gingival inflammation, characterized by erythema, oedema, and bleeding on probing could be detected.

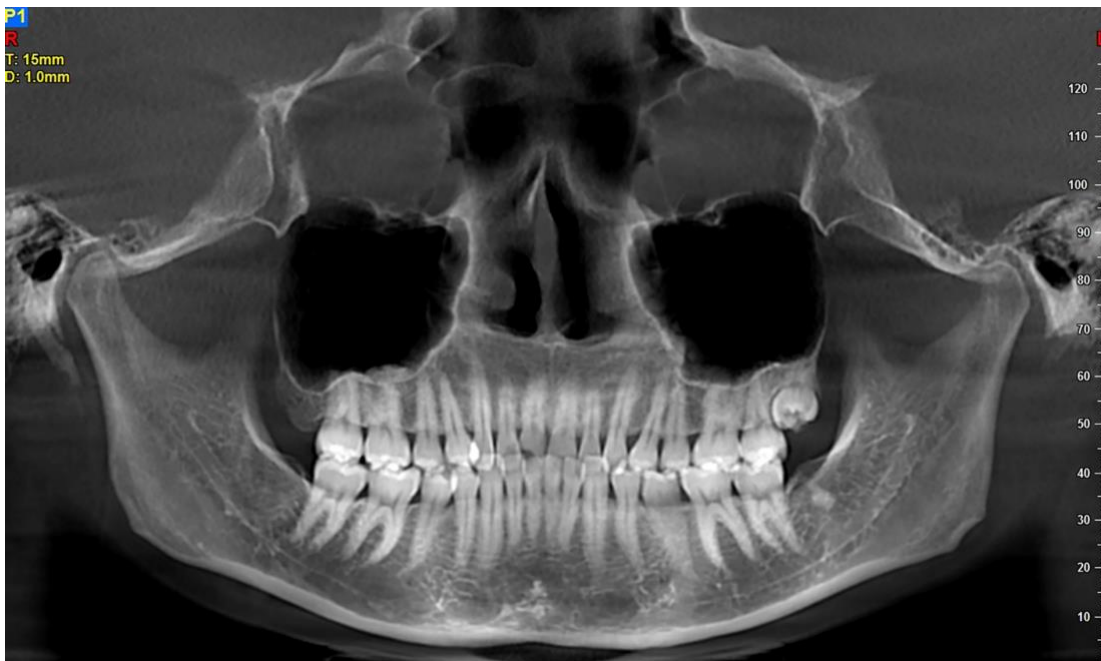

**Figure 1.** Facial and intraoral photographs taken at the initial visit.



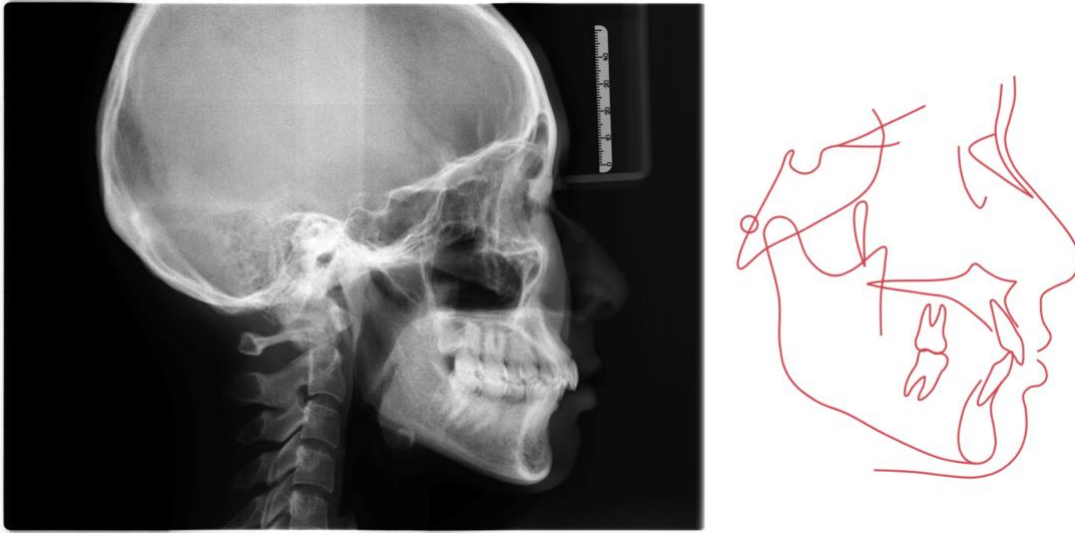
**Figure 2.** Pretreatment dental casts.

The initial CBCT (Figure 3) affirmed that the maxillary left third molar was impacted, and the right third molars were missing, and a root fragment of the mandibular left third molar was visible.



**Figure 3.** Panoramic radiograph sectioned from the initial CBCT.

The lateral cephalometric analysis (Figure 4, Table 1) revealed a skeletal Class I relationship with a reduced mandibular plane angle (ANB, 4.2°; FMA, 23.5°). The maxilla and mandible were basically normally placed, but it was worth noting that the ANB angle was elevated but still fell within the normal range. The mandibular incisors were mildly proclined (IMPA, 101.0°). The positioning of both the upper and lower lips was within the normal range (UL-EP, -1.5mm; LL-EP, 1.1mm).



**Figure 4.** Pretreatment lateral cephalogram and cephalometric tracing.

**Table 1.** Cephalometric measurements

Measurement	Normal	Pretreatment	Posttreatment	
SNA (°)	82.8±4.1	85.3	85.5	Skeletal
SNB (°)	80.1±3.9	81.1	81.0	
ANB (°)	2.7±2.0	4.2	4.5	
Wits (mm)	0.0±2.0	2.5	1.0	
FMA (°)	27.3±6.1	23.5	24.9	
SN-MP (°)	30.4±5.6	29.4	30.5	
U1-SN (°)	105.7±6.3	106.9	104.6	Dental
IMPA (°)	96.7±6.4	101.0	105.8	
Overjet (mm)	2.0±1.0	3.6	2.1	
Overbite (mm)	3.0±2.0	4.3	1.2	
Ptm-U6 (mm)	16.0±3.0	23.7	20.9	
UL-EP (mm)	-1.4±0.9	-1.5	-0.9	Soft Tissue
LL-EP (mm)	0.6±0.9	1.1	1.1	

SNA, sella-nasion-A point; SNB, sella-nasion-B point; ANB, A point-nasion-B point; FMA, gonion-menton to Frankfort horizontal plane; SN, sella-nasion; MP, mandibular plane; U1-SN, upper incisor to sella-nasion; IMPA, lower incisor to gonionmenton; Ptm-U6, pterygomaxillary fissure to upper first molar; UL-EP, upper lip to E line; LL-EP, lower lip to E line.

A diagnosis of Class I malocclusion was established, featuring a balanced facial profile, a reduced mandibular plane angle, and dental crowding.

The treatment objectives included alleviating crowding, aligning upper and lower dentitions, improving overbite and overjet, achieving a proper occlusion, enhancing smile esthetics and preserving the balanced facial profile.

Before commencing orthodontic treatment, a thorough and comprehensive evaluation of the patient's condition was conducted, accompanied by an in-depth discussion. Considering the patient's chief complaint regarding the malocclusion, which was mainly dental crowding, several strategies were explored to align the dentitions and attain an optimal occlusion.

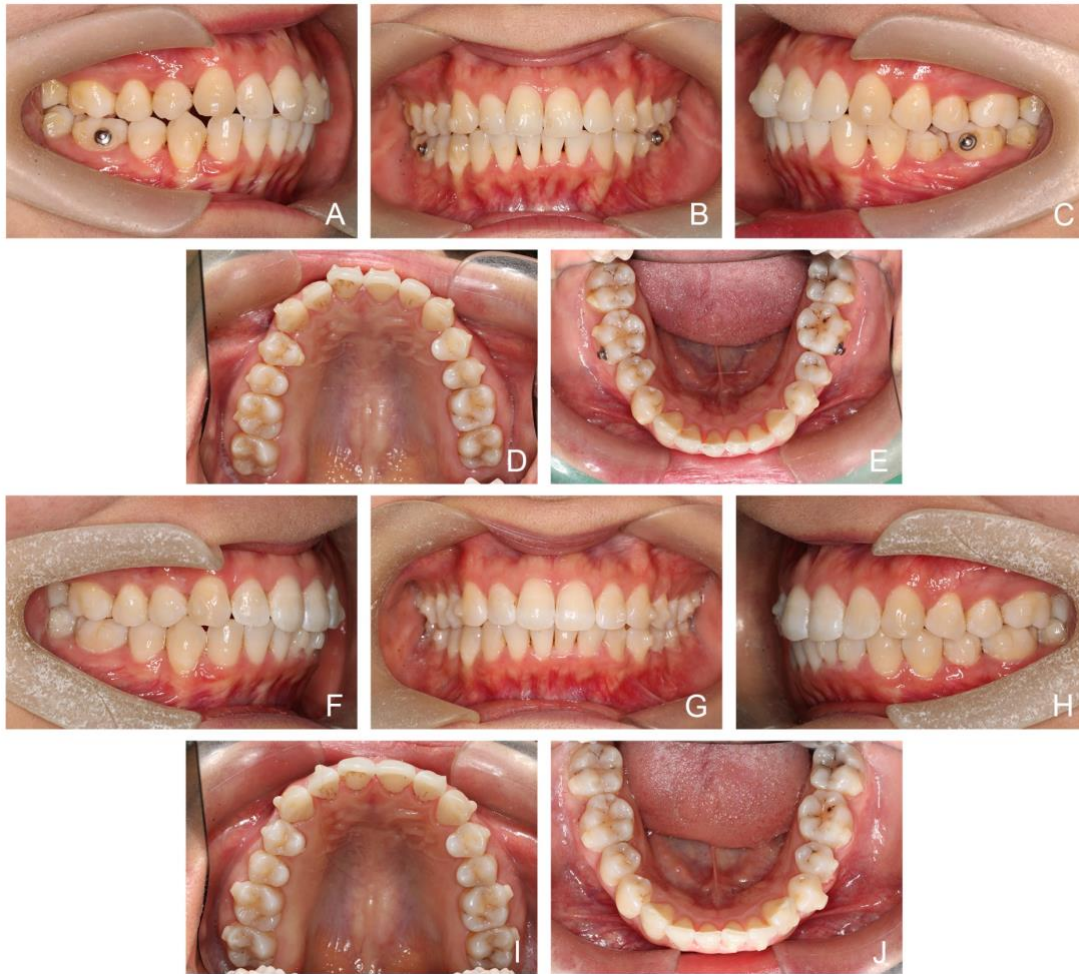If the patient consented to the extraction protocol, the removal of four premolars unquestionably represented the most straightforward and efficacious solution for alleviating crowding. Nonetheless, owing to a fear of tooth extraction, the patient declined to pursue this extraction treatment option.

The second treatment option involved the utilization of full fixed orthodontic appliances in conjunction with TADs to create sufficient space through molar distalization for tooth alignment. Due to the patient's occupational particularity and apprehension regarding miniscrew implant anchorage, this proposed treatment plan utilizing full fixed orthodontic appliances was also declined.

The third alternative entailed utilizing clear aligners (Invisalign, Align Technology, San Jose, CA, USA) for bimaxillary molar distalization and arch expansion, aiming to obtain sufficient space for tooth alignment and establish a proper occlusion. However, the challenge inherent in executing this treatment plan lied in the need for highly effective anchorage control strategies. The patient was informed about the importance of scheduled follow-up appointments during the treatment process. TADs should be promptly implanted upon any early signs of anchorage loss to aid in the treatment process. The patient was additionally apprised that, as part of the objective of the non-extraction treatment, the mandibular anterior teeth would be appropriately tilted labially to enhance the overbite and overjet. After receiving comprehensive information regarding both the benefits and drawbacks, the patient made the decision to move forward with this treatment option.

Prior to orthodontic treatment, comprehensive periodontal therapy, encompassing scaling and root planning, was carried out. Simultaneously, the patient was furnished with oral hygiene instructions. The prescribed tooth movement sequence for the orthodontic treatment process was formulated as follows: First, a reciprocal anchorage method was employed to achieve sequential distalization of the mandibular right molars and labial tipping of the mandibular anterior teeth. Bimaxillary arch expansion was synchronized simultaneously. Subsequently, after the crowding of the lower dentition was largely resolved and tooth alignment substantially improved, the initiation of sequential distalization of the maxillary right molars was undertaken with the assistance of Class II elastics. 70 aligner sets were initially designed for the orthodontic treatment, with instructions for the patient to switch to a new aligner set every 7 days and to wear each aligner set for a duration of at least 22 hours daily.

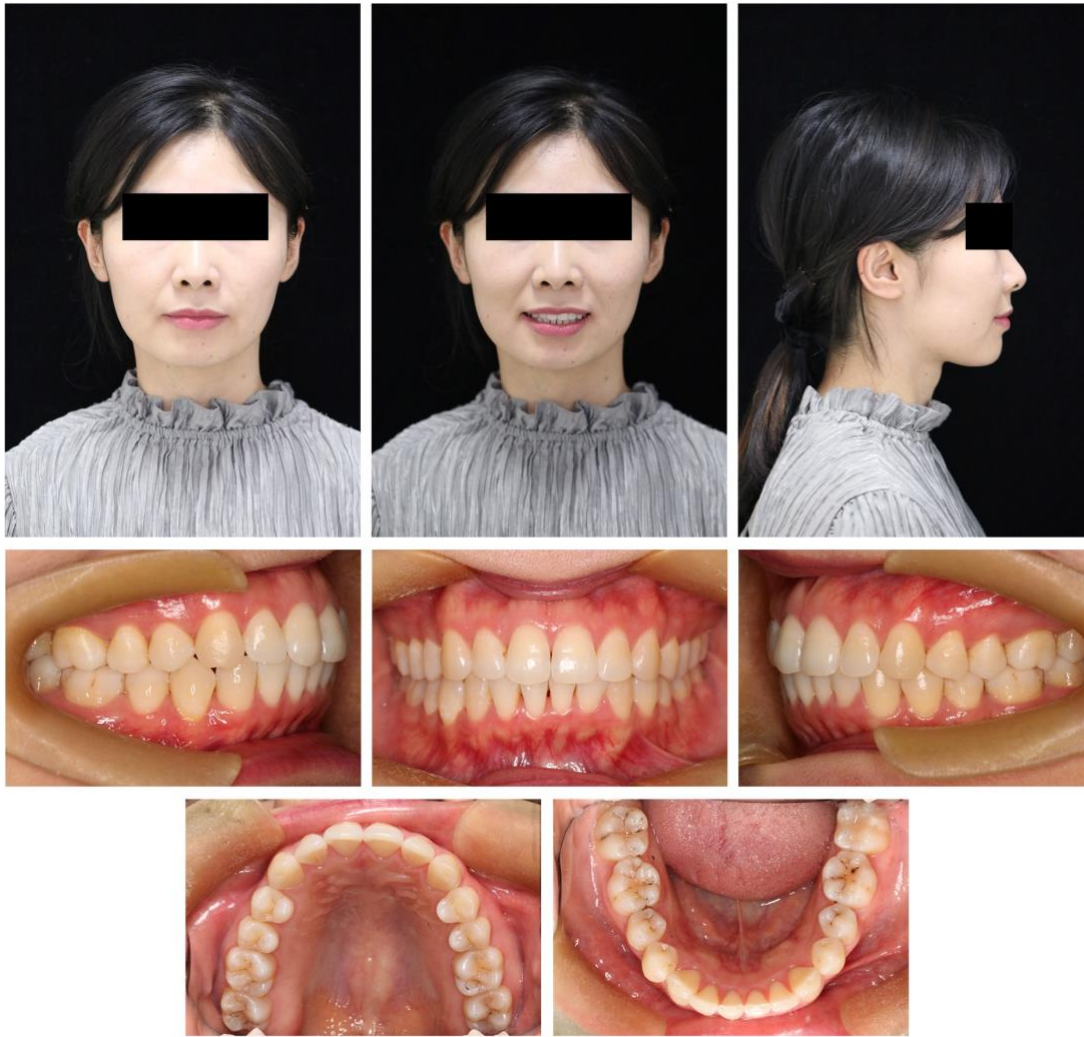After a 14-month treatment period, while the patient was wearing the stage 60 aligners, remarkable progress was observed (Figure 5 A~E). Both the upper and lower arches exhibited substantial widening, successful distalization of bimaxillary molars was achieved, dental crowding was significantly alleviated, and the anterior overbite and overjet showed notable improvements.



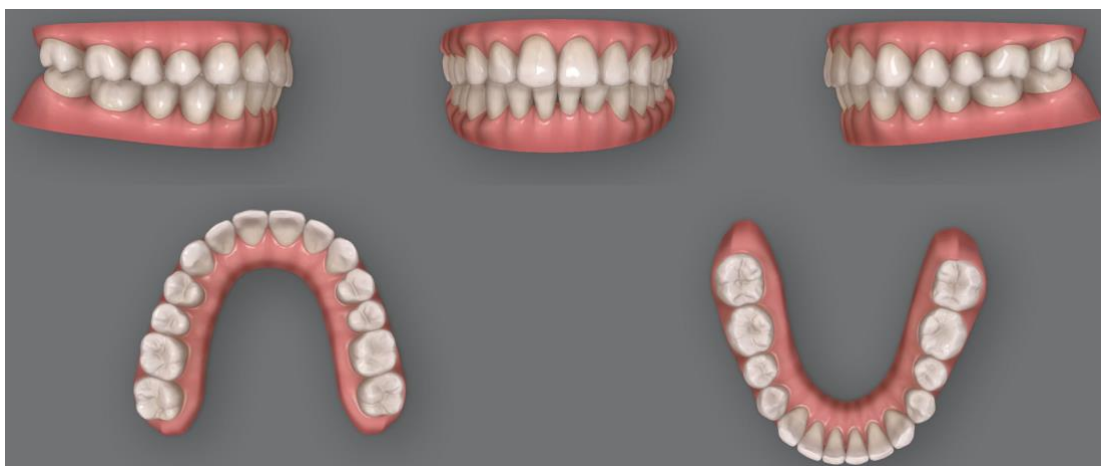**Figure 5.** Treatment progress. (A~E) Intraoral photographs taken at 14 months of treatment. (F~J) Intraoral photographs taken at 17 months of treatment.

At stage 70, after 17 months of treatment, with the exception of the maxillary right central incisor that remained slightly rotated, the malocclusion was basically corrected without noticeable aligner mismatch (Figure 5 F~J). Consequently, the decision to proceed with the final refinement was made. The refinement phase continued for about 3 months using 11 sets of aligners, aiming at executing the final tooth alignment and settling the occlusion. After that, all the treatment objectives were successfully achieved, and all attachments were removed. Vacuum-formed retainers were provided for retention. The patient was advised to wear them throughout the day for one year, followed by nighttime wear for at least one additional year. The overall treatment duration spanned approximately 22 months, with excellent patient compliance.

The posttreatment records (Figure 6 and 7) showcased the successful attainment of favorable tooth alignment, accompanied by optimal overbite and overjet, centered midlines, and bilateral Class I molar and canine relationships. The facial photographs displayed proper incisor exposure during smiling, preserving the initial balanced facial profile intact. The midlines of the upper and lower dentitions were coincident with the facial midline. All the treatment objectives were achieved.



**Figure 6.** Posttreatment facial and intraoral photograph.

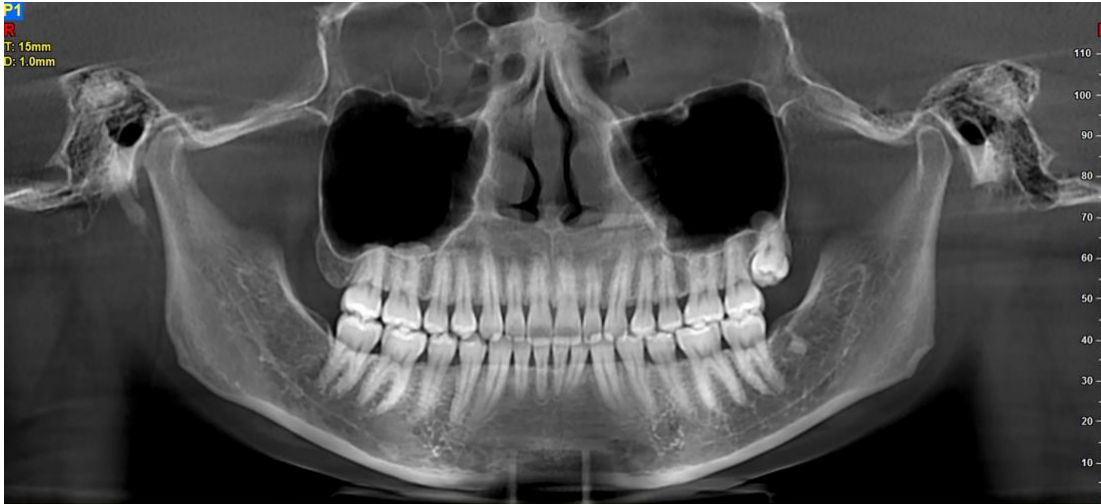

**Figure 7.** Posttreatment dental casts.

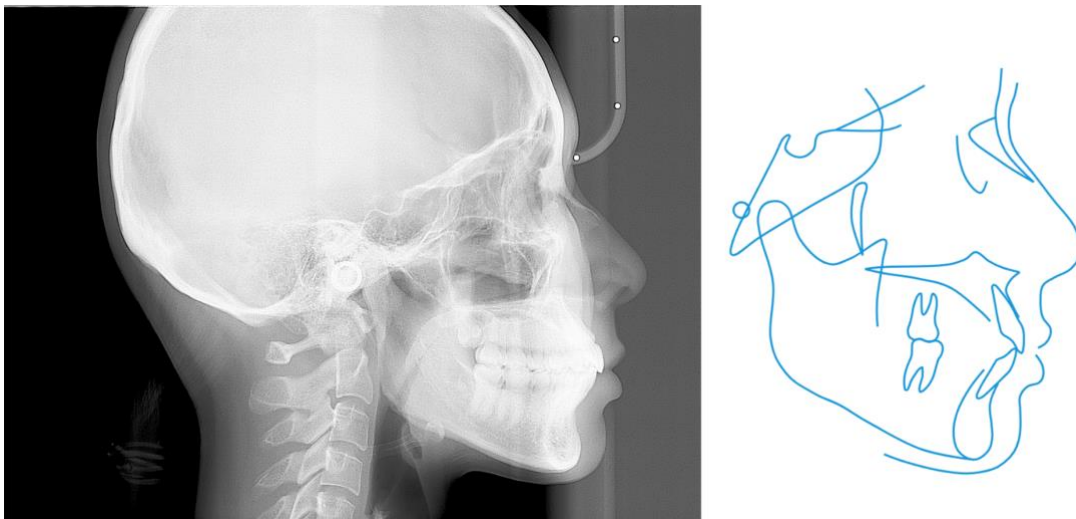
The posttreatment panoramic radiograph (Figure 8) displayed desirable root parallelism, with no apparent signs of root resorption or marginal bone loss. Based on the cephalometric analysis (Figure 9, Table 1) and



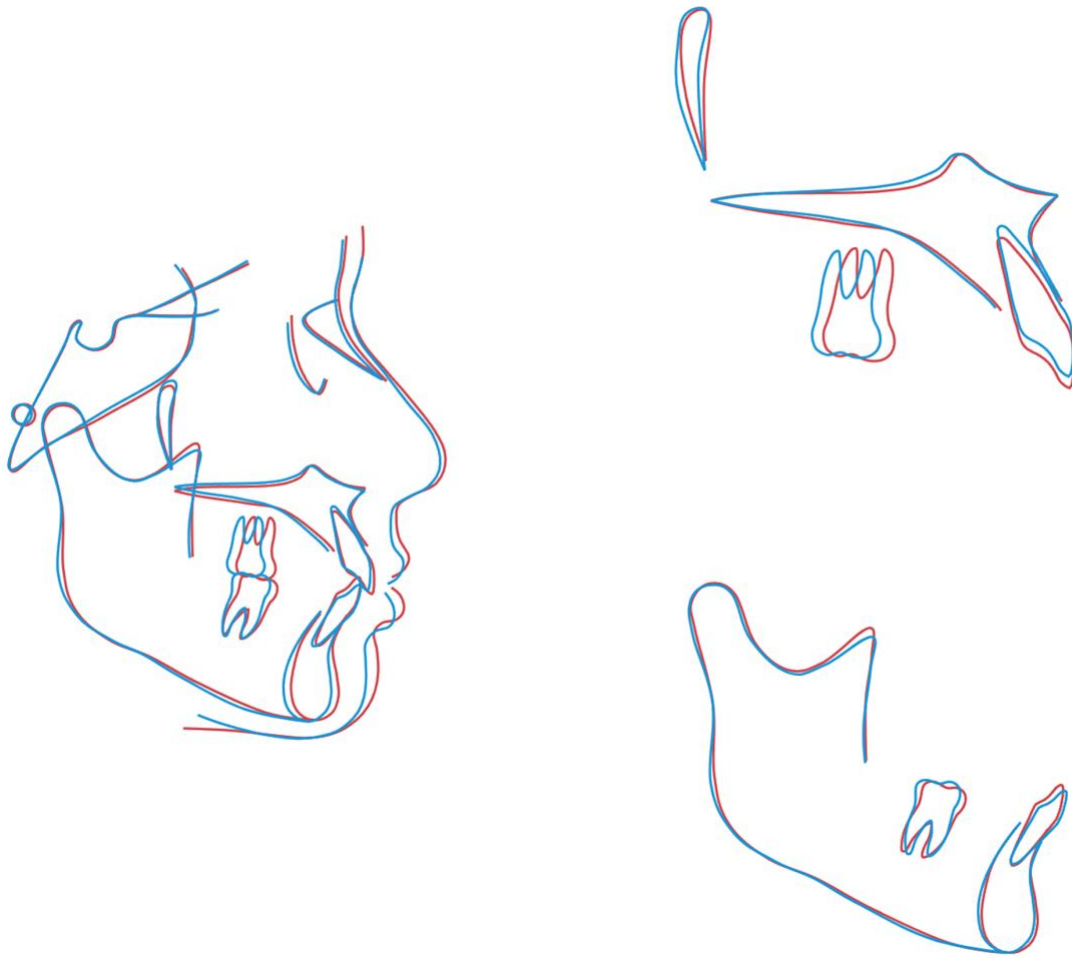
superimpositions (Figure 10), it was evident that bimaxillary molar distalization had been successfully achieved without labial tipping of the maxillary incisors. The Ptm-U6 had decreased by 2.8mm (from 23.7mm to 20.9mm) and the U1-SN had decreased by 2.3° (from 106.9° to 104.6°). Because the patient was an adult with negligible craniofacial growth during the short treatment period, the cephalometric superimposition was considered to be highly reliable. The superimposition of pretreatment and posttreatment CBCT images (Figure 11) showed that the mandibular right first molar was distalized by 2.7mm, and the maxillary right molars were distalized by 2.8mm.



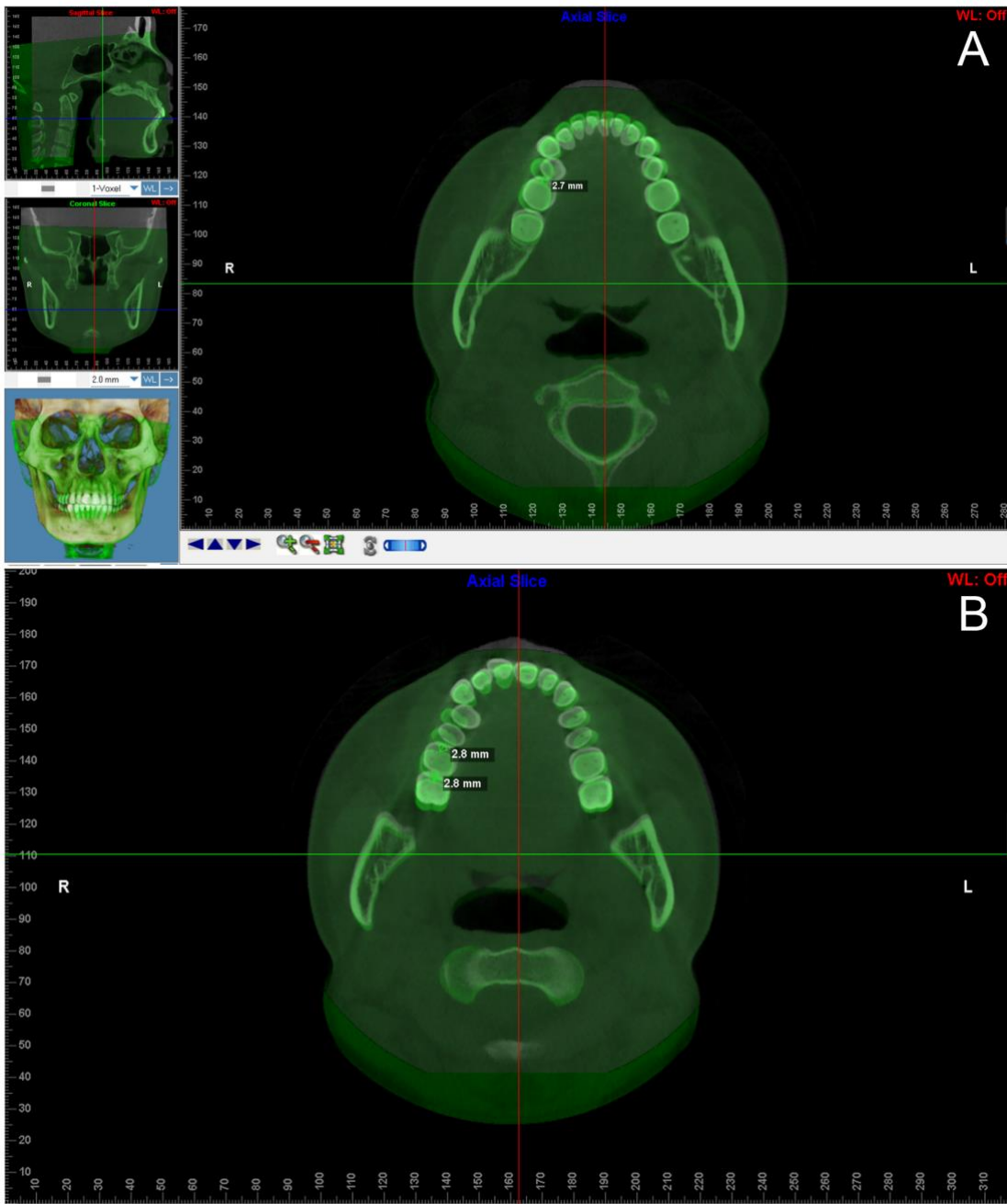
**Figure 8.** Panoramic radiograph sectioned from the posttreatment CBCT.



**Figure 9.** Posttreatment lateral cephalogram and cephalometric tracing.

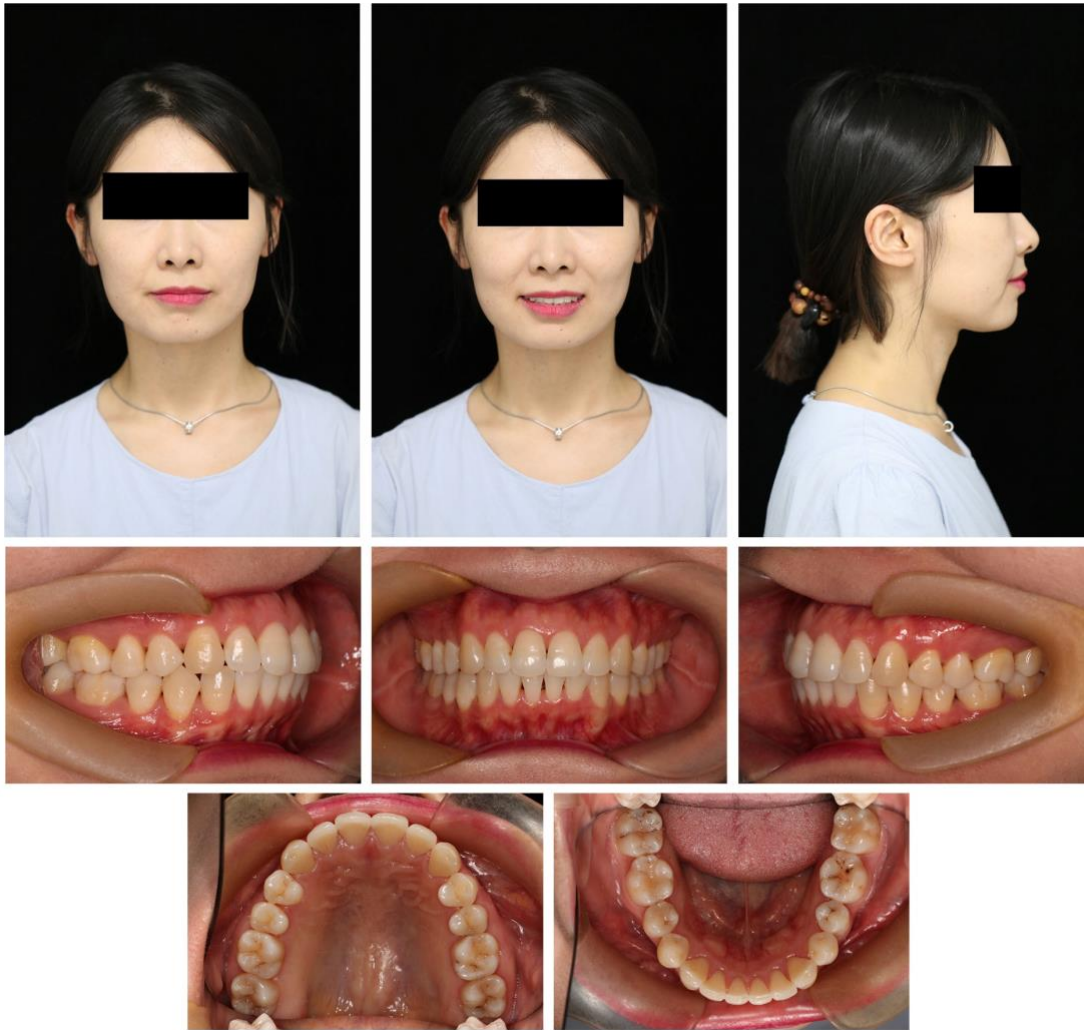

**Figure 10.** Cephalometric superimpositions (*red*: before treatment; *blue*: after treatment).



**Figure 11.** Superimposition of pretreatment and posttreatment CBCT images (*gray*: before treatment; *green*: after treatment). **(A)** The mandibular right first molar was distalized by 2.7mm. **(B)** The maxillary right molars were distalized by 2.8mm.

Excellent stability of the treatment outcomes, including optimal tooth alignment, pleasing occlusion and attractive smile, was confirmed by the follow-up records (Figure 12) taken approximately 2 years after the completion of orthodontic treatment.



**Figure 12.** Facial and intraoral photographs taken approximately 2 years after treatment.

## **DISCUSSION**

Adults frequently decline the use of conventional fixed labial orthodontic appliances due to concerns about their impact on esthetics. In response to evolving trends, clear aligners have emerged as a preferred option. Thanks to advancements in attachment technology and materials, clear aligners are now being employed for intricate tooth adjustments, such as tooth rotation, molar distalization, and arch expansion. In particular, clear aligners are renowned for their exceptional capability of achieving molar distalization. However, it was observed that the flaring of the anterior teeth was present in nearly all patients to varying degrees when auxiliary methods, apart from composite attachments, were not employed during the molar distalization procedure.<sup>[14]</sup> Hence, in orthodontic cases involving molar distalization where the avoidance of labial tipping of anterior teeth is necessary, the utilization of TADs is frequently inevitable to bolster anchorage. Especially when addressing the requirement for bimaxillary molar distalization, the importance of maintaining stable anchorage becomes even more pronounced. Currently, there have been case reports indicating that the use of TADs can effectively accomplish bimaxillary molar distalization.<sup>[15, 16]</sup> Nevertheless, cases of bimaxillary molar distalization utilizing clear aligners without the aid of TADs are seldom documented.

This case report may be considered a noteworthy example, demonstrating that, with a well-planned anchorage strategy, the need for TADs can be circumvented when performing bimaxillary molar distalization. In this specific non-extraction case, it is essential to be vigilant about the primary risk, which is labial tipping of the maxillary anterior segment that may occur as a consequence of anchorage loss during the maxillary molar distalization process. Therefore, it becomes imperative to implement suitable anchorage reinforcement measures during the maxillary molar distalization process. In the absence of TADs, using class II elastics stands as the optimal choice for safeguarding anchorage. Class II elastics are extensively employed in clear aligner treatment for the purpose of maxillary molar distalization. The combined utilization of Class II elastics and clear aligners demonstrates an effective capacity for enhancing anchorage.<sup>[17]</sup> By uniformly distributing biting force across the entire dental arch, clear aligners, through their bite-block mechanism, have the potential to counter undesired vertical component force generated by Class II elastics.<sup>[18]</sup> However, the Class II elastic force applied to mandibular first molars can be broken down into two components: upward and mesial forces, with the mesial component exerting the greatest influence. For this patient, if Class II elastics are applied, the mesial component force could have a detrimental impact on the mandibular molar distalization process. That is to say, it is not advisable to attempt simultaneous distalization of both maxillary and mandibular molars for this patient. The sequence should prioritize mandibular molar distalization, followed by maxillary molar distalization, with the latter being reinforced by Class II elastics. Despite the pronounced crowding in the lower dentition of this patient, it was imperative to achieve controlled labial tilting of the mandibular anterior teeth within the context of a non-extraction treatment plan. Therefore, in this scenario, the distalization of the mandibular molars could harness the reactionary force generated by labially tilting the anterior teeth as the primary source of anchorage. In other words, the acquisition of the space for the mandibular tooth alignment could be accomplished by extending the arch length through a system of anterior-posterior reciprocal anchorage. Up to this point, the anchorage design concept for clear aligner treatment in cases resembling this patient has become clear: First, it is imperative to commence with distalization of the mandibular molars, concurrently employing a reciprocal anchorage approach to labially tilt the mandibular anterior teeth. Once the mandibular molars are appropriately distalized, the maxillary molar distalization process can initiate with the application of Class II elastics, thereby achieving the objective of bimaxillary molar distalization.

Looking back at this case, another crucial point for achieving the treatment objectives successfully is bimaxillary arch expansion. Lione et al<sup>[19]</sup> confirmed that clear aligners have the potential to achieve arch expansion. However, there are variations in the reported realization rates of arch expansion among different researchers.<sup>[20, 21]</sup> Currently, there is a lack of a definitive efficiency value for arch expansion in the literature pertaining to clear aligners. But it is established that clear aligners cannot achieve 100% arch expansion efficiency. Orthodontists must incorporate a degree of overcorrection into their treatment planning based on clinical expertise and the specific characteristics of the patient's condition. Based on the treatment outcomes observed in this case, it can be concluded that clear aligners have demonstrated relatively effective arch expansion capabilities.

The patient had slight mandibular retrognathia, and the mandibular incisors were protrusive before treatment. Nevertheless, as part of the orthodontic treatment, there was a requirement to level the curve of Spee and enhance the overjet, overbite, and canine relationship. To achieve an improved occlusion, it was necessary to further labially tilt the mandibular anterior teeth. Consequently, after treatment, the mandibular incisors exhibited excessive protrusion in comparison to normal, which ultimately represented a drawback in this case.

## CONCLUSIONS

With a well-considered anchorage plan, clear aligners can successfully achieve bimaxillary molar distalization without the necessity of TADs. In the absence of TADs, it is essential to perform the distalization procedures for the maxillary and mandibular molars separately, utilizing intermaxillary elastics to reinforce anchorage. This approach helps prevent undesired labial tipping of the anterior teeth, ensuring a more effective and controlled orthodontic treatment. In addition, clear aligners are effective for both maxillary and mandibular arch expansion.

## ETHICS APPROVAL AND CONSENT TO PARTICIPATE

The study was approved by the Research Ethics Committee of Yantai Stomatological Hospital and accepted by the patient. Written informed consent was obtained from the patient for publication of this case report and accompanying images.

## AVAILABILITY OF DATA AND MATERIALS

The data used to support the findings of this study are available from the corresponding author upon request.

## CONFLICT OF INTEREST

The authors declare no conflict of interest.

## FUNDING

This study received no external funding.

## AUTHOR CONTRIBUTIONS

Concept: Kun Li, Peng Sun, Deming Yu.

Design: Deming Yu.

Data acquisition: Kun Li, Hui Li.

Data analysis: Kun Li, Hui Li.

Literature search: Kun Li, Peng Sun, Deming Yu.

Manuscript preparation: Kun Li.

Manuscript editing and review: Peng Sun, Deming Yu.

The manuscript has been read and approved by all the authors, and each author believes that the manuscript represents honest work. The requirements for authorship as stated in Authorship Criteria have been met.

## ACKNOWLEDGMENTS

The authors would like to thank all professionals who participated in the management of this case.

## REFERENCES

1. Montasser MA, Taha M. Relationship between dental crowding, skeletal base lengths, and dentofacial measurements. *Prog Orthod.* 2012;13(3):281-7.
2. Jung MH. Total arch distalization with interproximal stripping in a patient with severe crowding. *Korean J Orthod.* 2019;49(3):194-201.

3. Kinzinger GS, Eren M, Diedrich PR. Treatment effects of intraoral appliances with conventional anchorage designs for non-compliance maxillary molar distalization: a literature review. *Eur J Orthod.* 2008;30(6):558-71.
4. Patel MP, Henriques JF, Freitas KM, Grec RH. Cephalometric effects of the Jones Jig appliance followed by fixed appliances in Class II malocclusion treatment. *Dental Press J Orthod.* 2014;19(3):44-51.
5. Shpack N, Brosh T, Mazor Y, Shapinko Y, Davidovitch M, Sarig R, et al. Long- and short-term effects of headgear traction with and without the maxillary second molars. *Am J Orthod Dentofacial Orthop.* 2014;146(4):467-76.
6. Ke Y, Zhu Y, Zhu M. A comparison of treatment effectiveness between clear aligner and fixed appliance therapies. *BMC Oral Health.* 2019;19(1):24.
7. Simon M, Keilig L, Schwarze J, Jung BA, Bourauel C. Treatment outcome and efficacy of an aligner technique--regarding incisor torque, premolar derotation and molar distalization. *BMC Oral Health.* 2014;14:68.
8. Ravera S, Castroflorio T, Garino F, Daher S, Cugliari G, Deregibus A. Maxillary molar distalization with aligners in adult patients: a multicenter retrospective study. *Prog Orthod.* 2016;17:12.
9. Caruso S, Nota A, Ehsani S, Maddalone E, Ojima K, Tecco S. Impact of molar teeth distalization with clear aligners on occlusal vertical dimension: a retrospective study. *BMC Oral Health.* 2019;19(1):182.
10. Galan-Lopez L, Barcia-Gonzalez J, Plasencia E. A systematic review of the accuracy and efficiency of dental movements with Invisalign®. *Korean J Orthod.* 2019;49(3):140-9.
11. Robertson L, Kaur H, Fagundes N, Romanyk D, Major P, Flores Mir C. Effectiveness of clear aligner therapy for orthodontic treatment: A systematic review. *Orthod Craniofac Res.* 2020;23(2):133-42.
12. Li L, Guo R, Zhang L, Huang Y, Jia Y, Li W. Maxillary molar distalization with a 2-week clear aligner protocol in patients with Class II malocclusion: A retrospective study. *Am J Orthod Dentofacial Orthop.* 2023;164(1):123-30.
13. Liu X, Cheng Y, Qin W, Fang S, Wang W, Ma Y, et al. Effects of upper-molar distalization using clear aligners in combination with Class II elastics: a three-dimensional finite element analysis. *BMC Oral Health.* 2022;22(1):546.
14. Saif BS, Pan F, Mou Q, Han M, Bu W, Zhao J, et al. Efficiency evaluation of maxillary molar distalization using Invisalign based on palatal rugae registration. *Am J Orthod Dentofacial Orthop.* 2022;161(4):e372-372e379.

15. Alshehri A. Bimaxillary Distalization with Skeletal Anchorage for Management of Severe Skeletal Class III Open Bite Malocclusion. *Children (Basel)*. 2022;9(11).
16. Vasoglou G, Patatou A, Vasoglou M. Bimaxillary Dentoalveolar Protrusion Case Treated with Anchorage by Buccally Implemented Mini-Implants Using a 3D-Printed Surgical Guide. *Children (Basel)*. 2023;10(5).
17. Amm E, El Amm C, Vaden J. Effect of Class II elastics on different mandibular arch preparation stabilized with aligners and stainless-steel wires: A FEM study. *Orthod Craniofac Res*. 2022;25(4):520-9.
18. Liu X, Wang W, Gao J, Qin W, Wen Y, Luo H, et al. Actual contribution ratio of maxillary and mandibular molars for total molar relationship correction during maxillary molar sequential distalization using clear aligners with Class II elastics: A finite element analysis. *Am J Orthod Dentofacial Orthop*. 2023;164(4):e106-106e120.
19. Lione R, Paoloni V, Bartolommei L, Gazzani F, Meuli S, Pavoni C, et al. Maxillary arch development with Invisalign system. *Angle Orthod*. 2021;91(4):433-40.
20. Houle JP, Piedade L, Todescan R Jr, Pinheiro FH. The predictability of transverse changes with Invisalign. *Angle Orthod*. 2017;87(1):19-24.
21. Zhou N, Guo J. Efficiency of upper arch expansion with the Invisalign system. *Angle Orthod*. 2020;90(1):23-30.



Published by MM Publishers

<https://www.mmpubl.com/ijorthrehab>



This is an open access journal, and articles are distributed under the terms of the Creative Commons Attribution-Non Commercial 4.0 International License, which allows others to remix, tweak, and build upon the work non-commercially, as long as appropriate credit is given, and the new creations are licensed under the identical terms.

To view a copy of this license, visit <http://creativecommons.org/licenses/by-nc/4.0/> or send a letter to Creative Commons, PO Box 1866, Mountain View, CA 94042, USA.

Copyright © 2024, Kun Li, Peng Sun, Hui Li, Deming Yu